Refresher Course 2017

BAPA in collaboration with SKA

Belgian Associaton
For Paediatric Anaesthesiology

Difficult Vascular Access in Children

Tilburg - 11 march 2017

Dr Th. Pirotte
Pediatric Anesthesia - UCL - Brussels

CLINIQUES UNIVERSITAIRES SAINT-LUC

Vascular Access in children

- Interest for VA - books & courses - is still limited ←
  compared to Nerve Blocks for example.
- VA is mandatory for every case (at least a PVA, sometimes a CVA); NB not.

- Difficult Access :
  - peripheral: predictable (skin) ←
  - central: surprises (under the skin) ←
  - skills - Tips - Tricks & devices ←←←

Inhalational Anesthesia

- Often the first choice

- not finding a iv

- Laryngospasm without iv !

- Algorithm ?

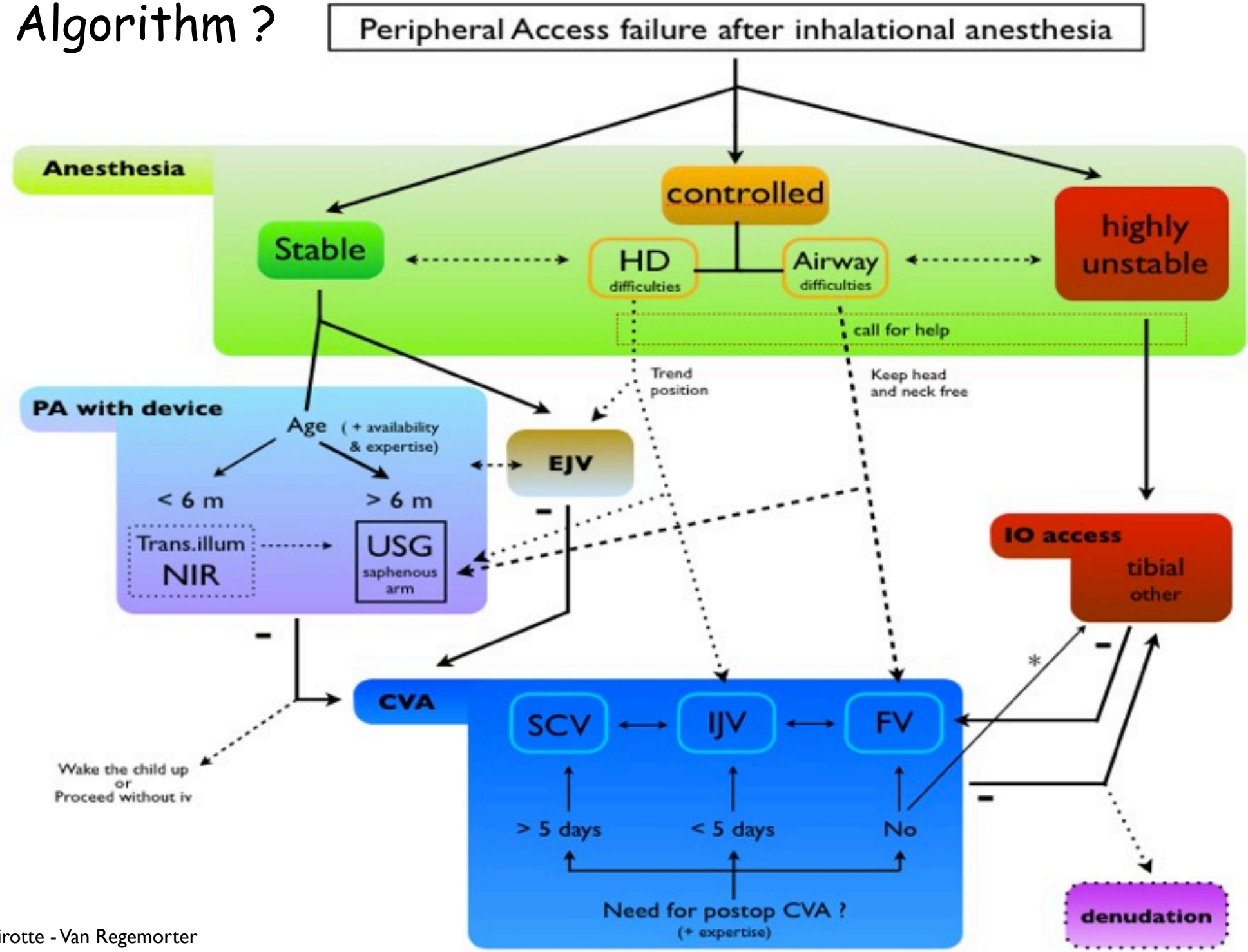

Pirotte - Van Regemorter
submitted

Intraosseous Access

- Should be available in every Operating Theater
- Large education and <u>information</u> → Storage ?
  Known by everybody
- ... to never have to use it

in 3 years time : 12 needles used
... all for workshops

- Demystification
  - easy
  - complications = rare

Intraosseous Access

- Should be available in every Operating Theater
- Large education and <u>information</u> → Storage ?
  Known by everybody
- ... to never have to use it

in 3 years time : 12 needles used
... all for workshops

- Demystification
  - easy
  - complications = rare

- extravasation : 4-12% (in OR ?)
- compartment syndrome : 0,6% ---------- CI: - previous attempt same bone
- osteomyelitis: 0,5% ---------- CI: - local infection

- fracture ---------- CI: - osteogenesis imperfecta
- lesion of the growth plate
- fat embolism ---------- CI: - R-L intracardiac shunt

Indications IO Access

- NO iv access + highly unstable child:
  - cardiac arrest
  - unstable trauma (only access possible with all the veins flat/empty)
  - major events after inhalational anesthesia
- Prevention:
  - device ready at induction if combination:
  - known DIVA + potential difficult airway

    - child with a cold
    - obesity
    - Pierre-Robin,...

  - especially in remote locations

- prevention: IO device ready…

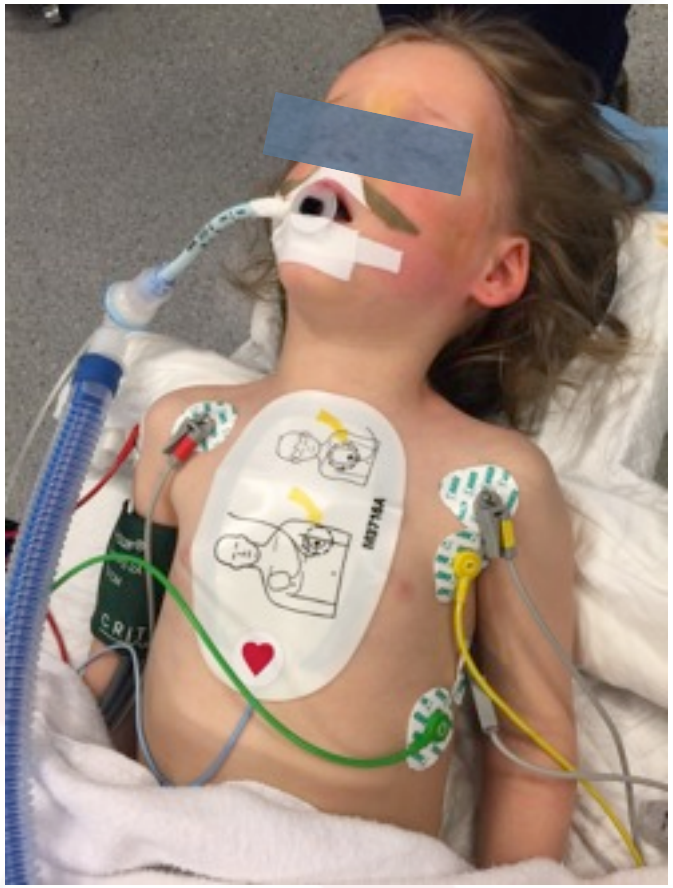

- 3 years old
- strabismus surgery
- complete AV block

- inhalational induction

- easy and rapid iv

- IO access not needed

- 8 months - 11kg
- MRI (remote location)
- Cushing syndrome - Adrenal gl.
- awake iv impossible
- inhalational induction

- iv inner wrist
- 2d iv : USG saphenous

- IO access not needed

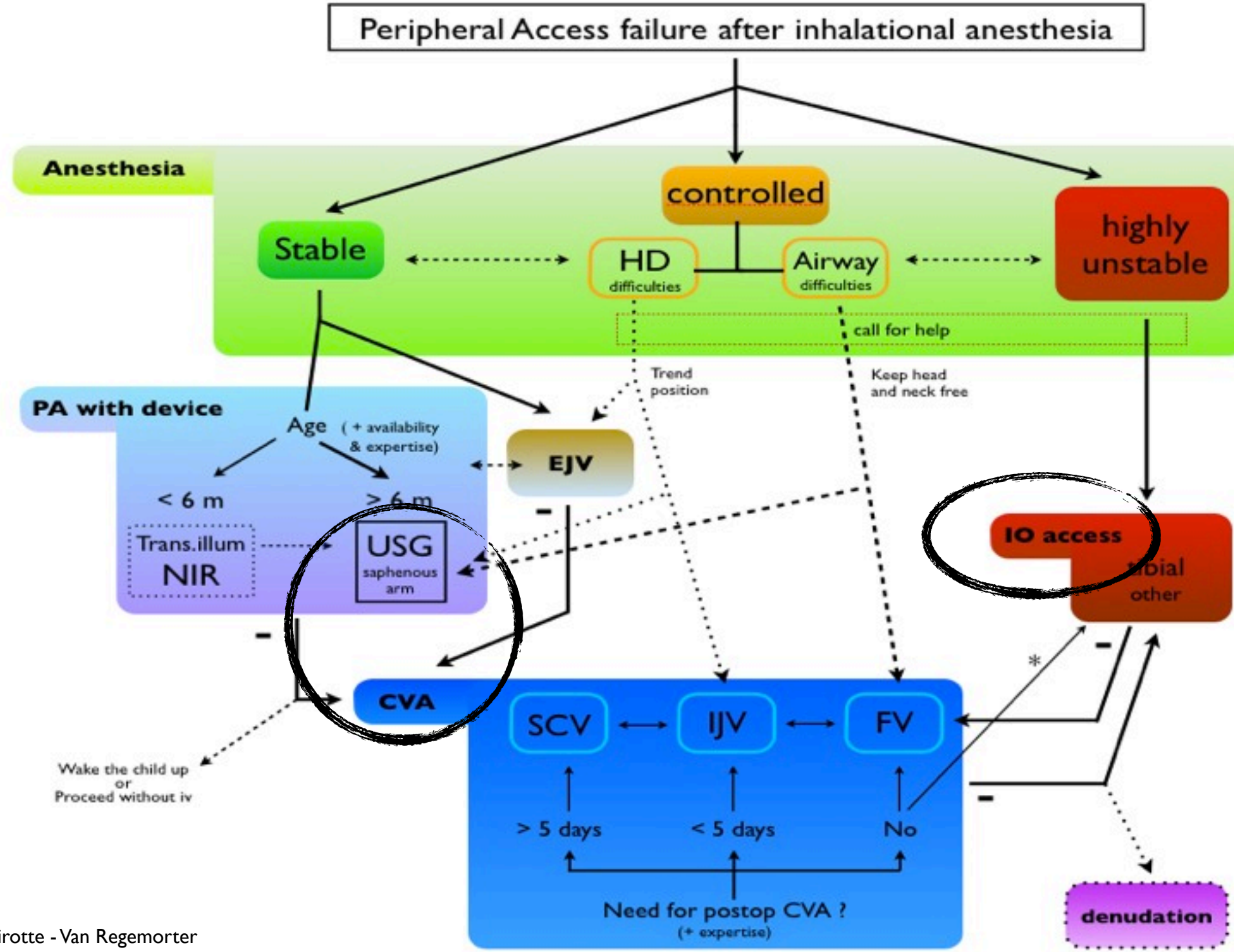

Pirotte - Van Regemorter
submitted

Site

Flat aspect of the tibia

Infants:

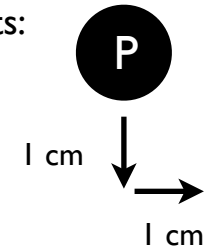

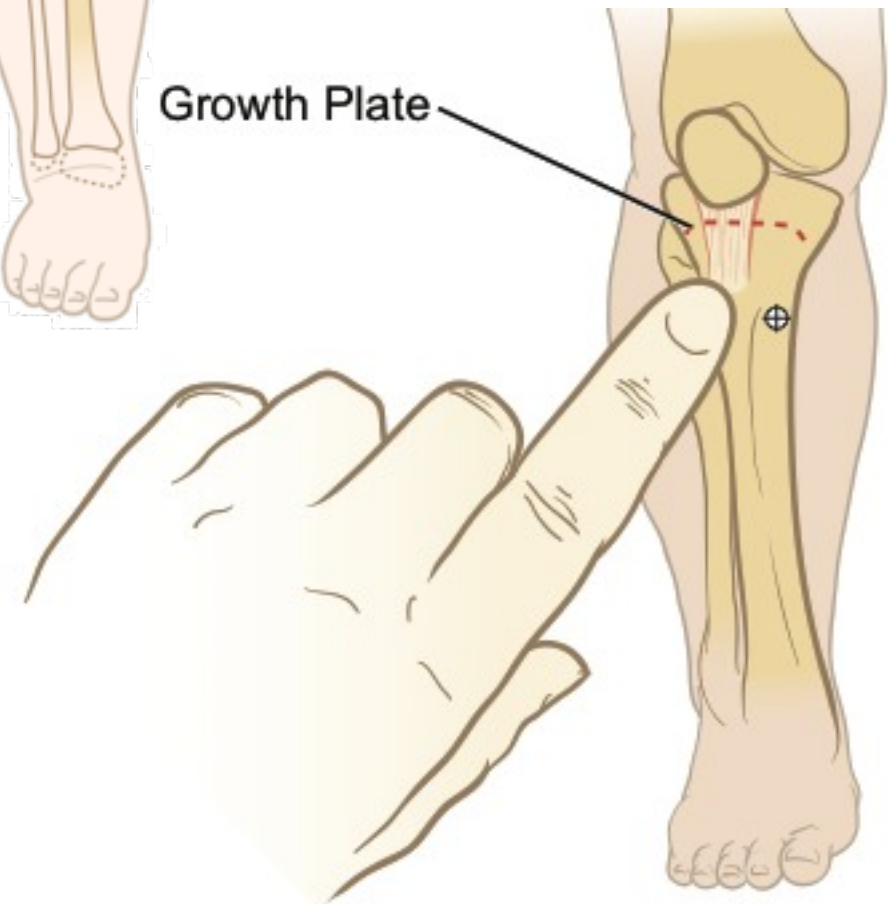

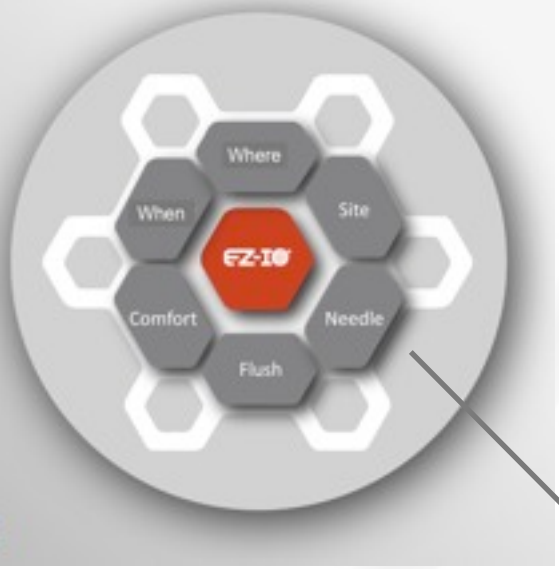

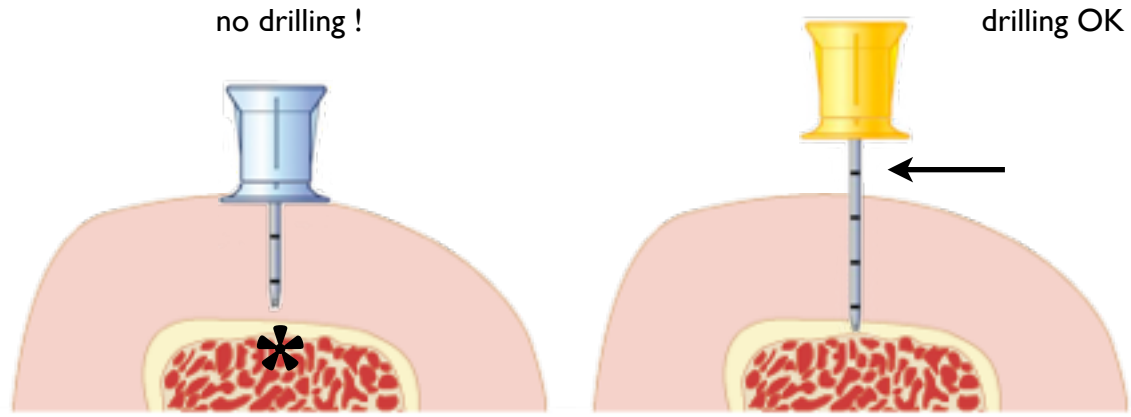

Needle

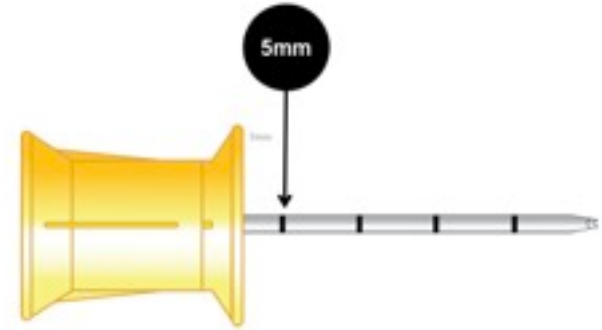

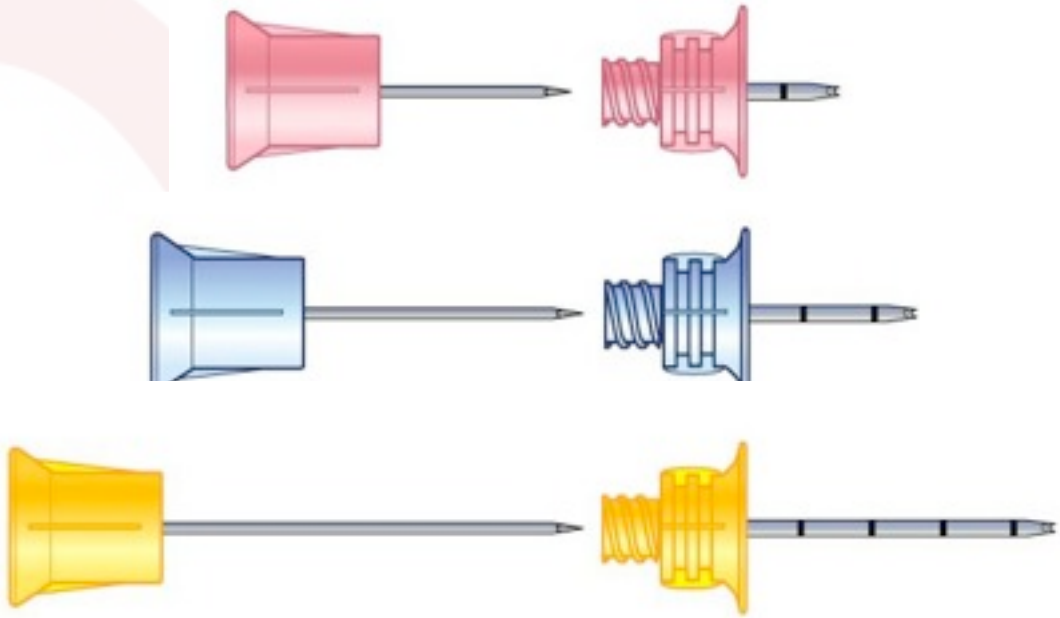

15 mm	3-39 kg
25 mm	> 3 kg
45 mm	> 40 kg , soft tissue +++

Flush

5 to 10 ml

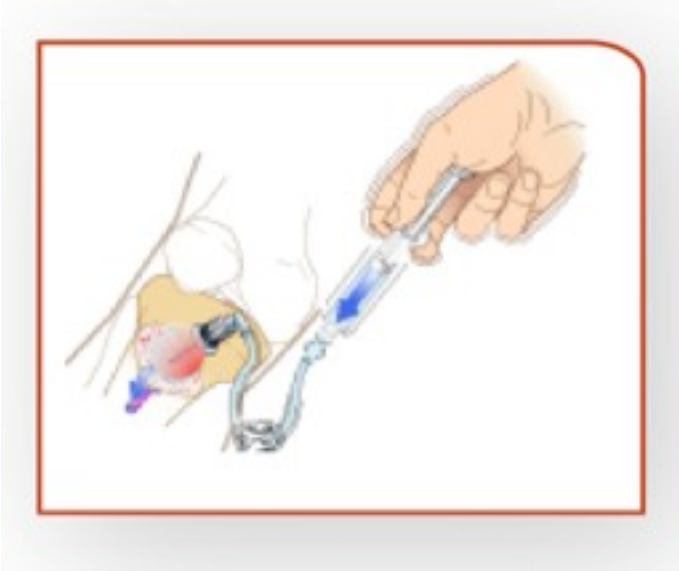

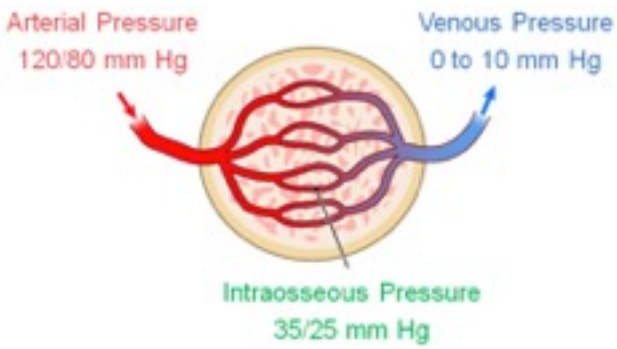

approx 1/3 arterial pressure

Peripheral Access

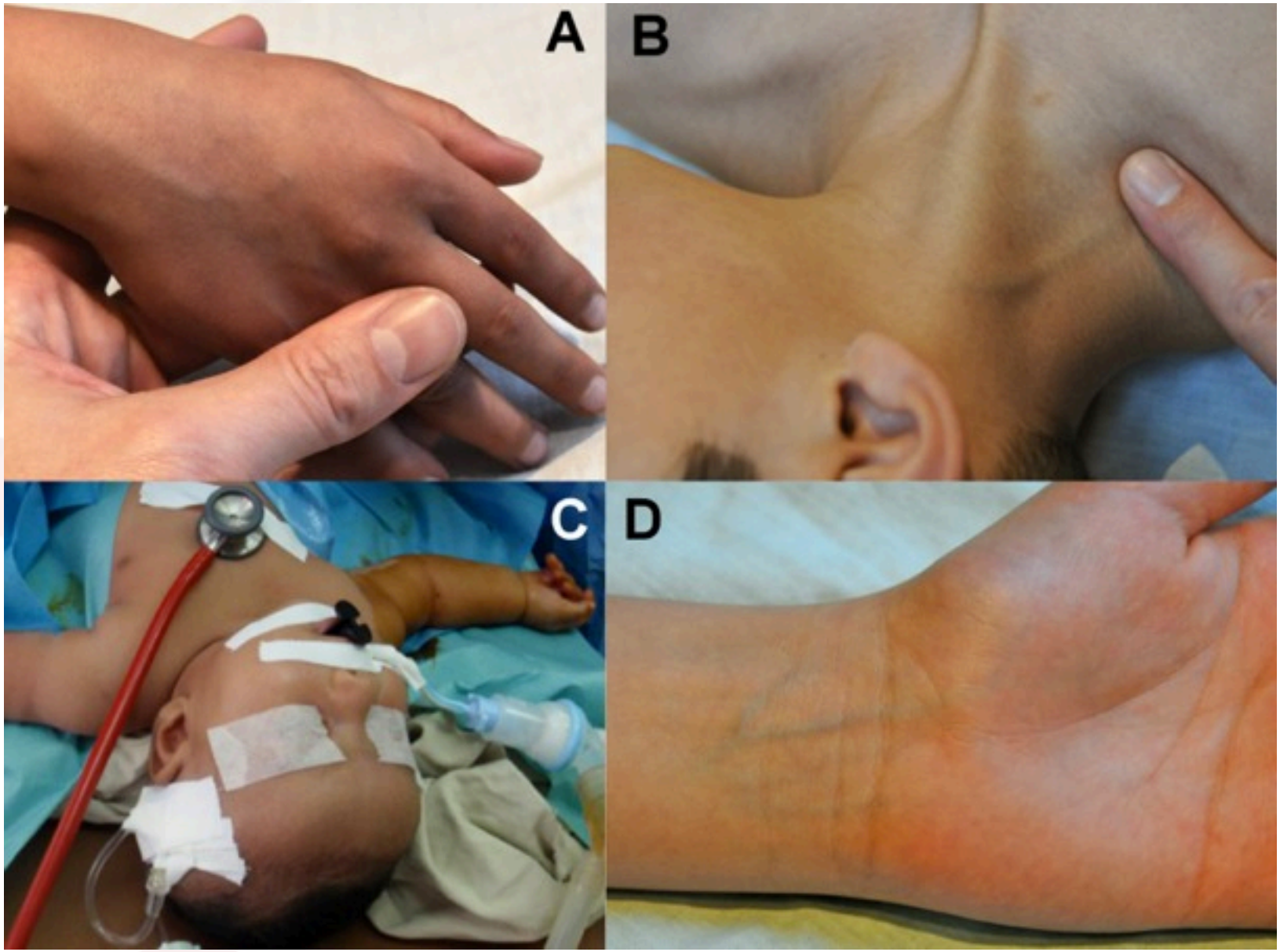

Peripheral Access

- Difficulties are predictable : clinical examination & history

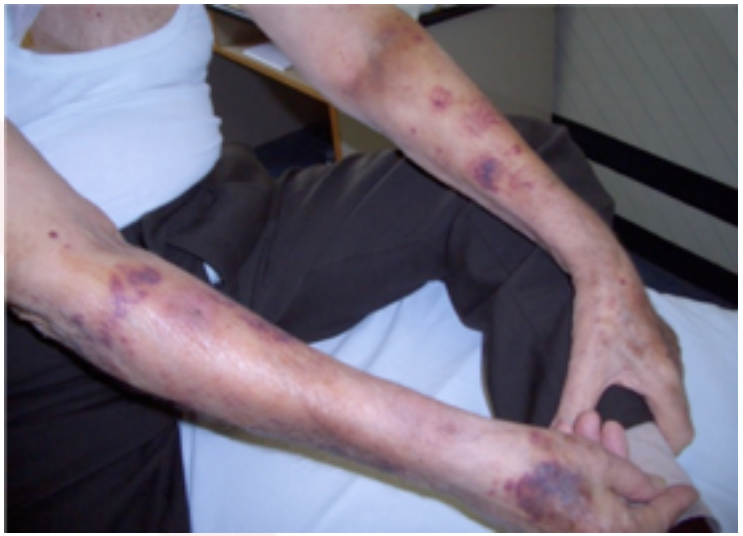

. chronic illness

. black skin

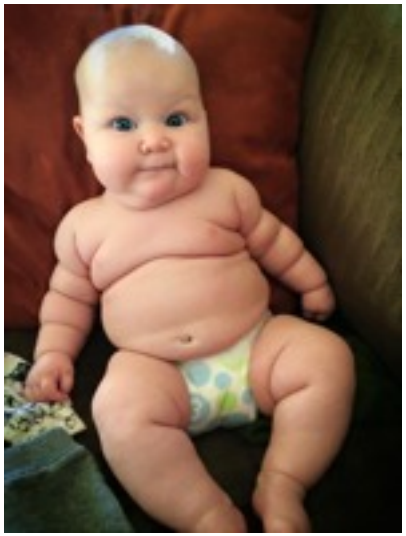

. happy mommy's child

Peripheral Access

DIVA score (Yen - 2008)

	0 point	1 point	2 points	3 points
visibility of the vein	visible		not visible	
palpation of the vein	palpation		no palpation	
age	> 3 years	1-2 years		< 1 year
history of prematurity	term			preterm

DIVA

≥ 4

= !!

(chronic illness, obesity, previous DIVA ,...)

- In the OR:
  - first attempt success = 70-80%
  - impossible = 0,3% (ward = up to 5%)
  - & experience (years of practice , nb / week)

- Tips & Tricks ?

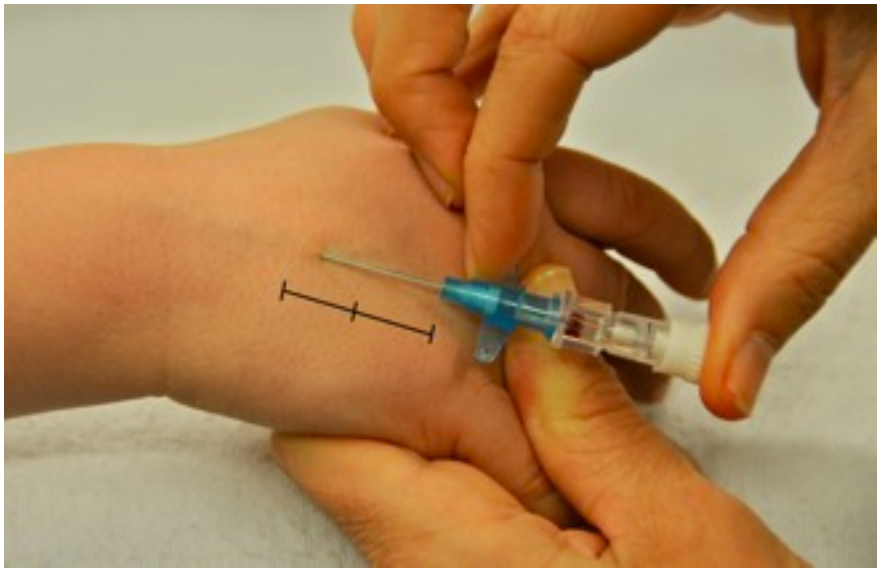

  - wet a black skin (often dry)
  - take EMLA off 5 min. before
  - warm up the hand of foot (water, glove, B.Hugger)
  - push the needle with the thumb («clic»)
    - wait for back flow in neonates (up to 2")
    - or fill the needle with saline («swimming RBC»)
  - use only half of the needle length to find the vein
  - 2d half should be catheterized (reduce postop extravasation)

Devices for PVA ?

- Vein Entry Indicator Device (VEID)

  - acoustic pressure monitoring
  - some benefit when difficult
  (no vein visible & slow blood entry)



- Transillumination (VeinLite)

- increase success when < 2 years old
- some benefit when difficult (slow blood entry)
- experience / dark environment !, no depth!

Veinlite EMS side-transillumination method to visualize veins.

www.AliExpress.com

?

www.alibaba.com

Devices for PVA ?

- NIR technology

- controversial efficacy: better visibility - same success rate
- screening (dark skin, hematoma) ?
- bifurcation - flushing ok
- no depth

VeinViewer Flex

VeinViewer

VeinSite

- NIR technology

Near-infrared light to aid peripheral intravenous cannulation in children: a cluster randomised clinical trial of three devices*

J. C. de Graaff,[1] N. J. Cuper,[2] R. A. A. Mungra,[3] K. Vlaardingerbroek,[4] S. C. Numan[4] and C. J. Kalkman[5]

Anaesthesia 2013, 68, 835–845

doi:10.1111/anae.12294

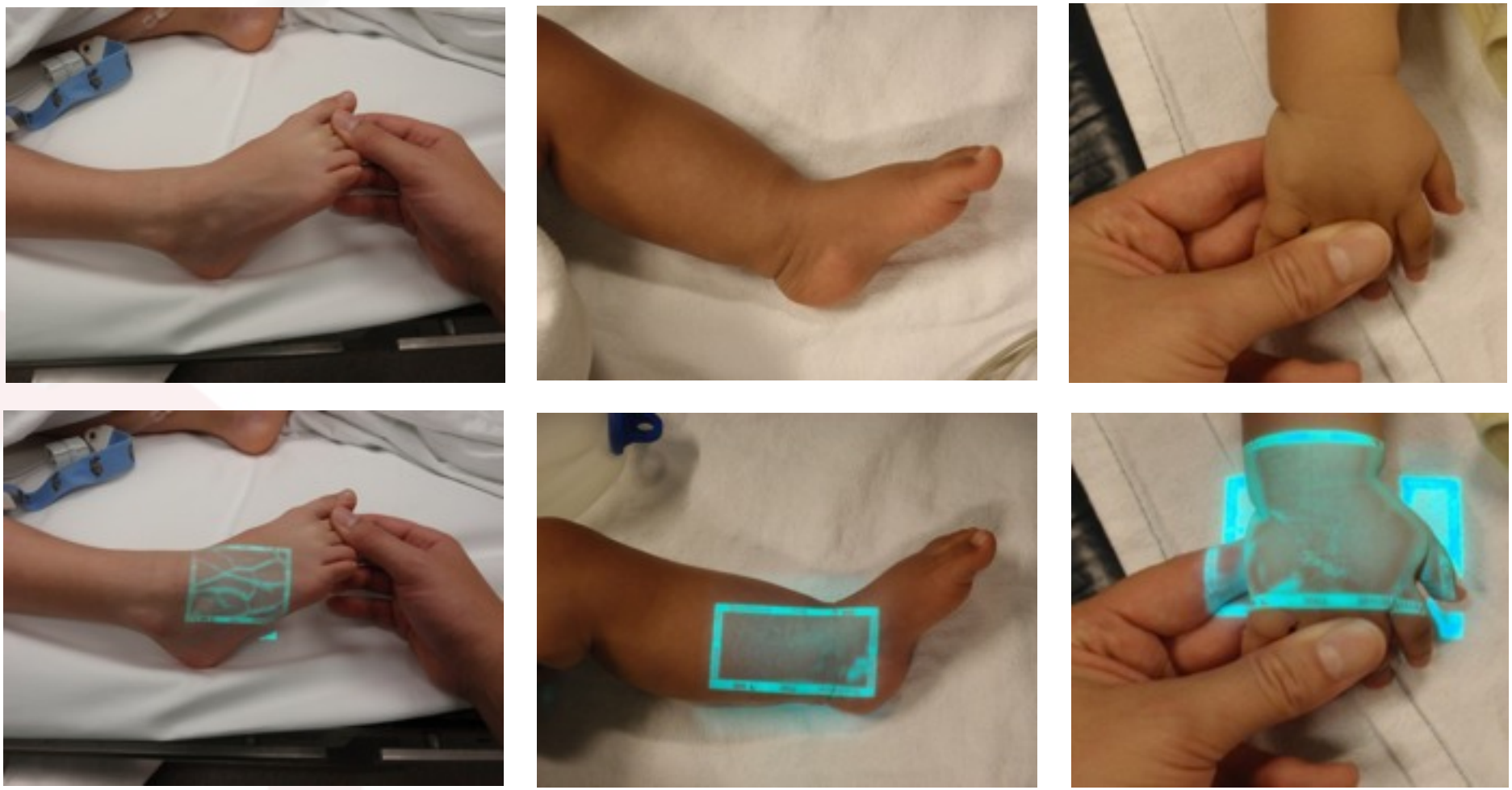

Devices for PVA ?

- Ultrasound Guidance (> Transillum., > NIR)
  - increase success rate and reduce time in case of difficult PVA
  - could reduce need for CVC or IO
  - recommended by several societies
  - ankle, antecubital fossa, arm (picc-, mid-lines)
  - asleep >> awake (!!)

- Internat EB reco (2012): Int Care Medecine
- French guidelines (2015): Anaesth Crit Care Med

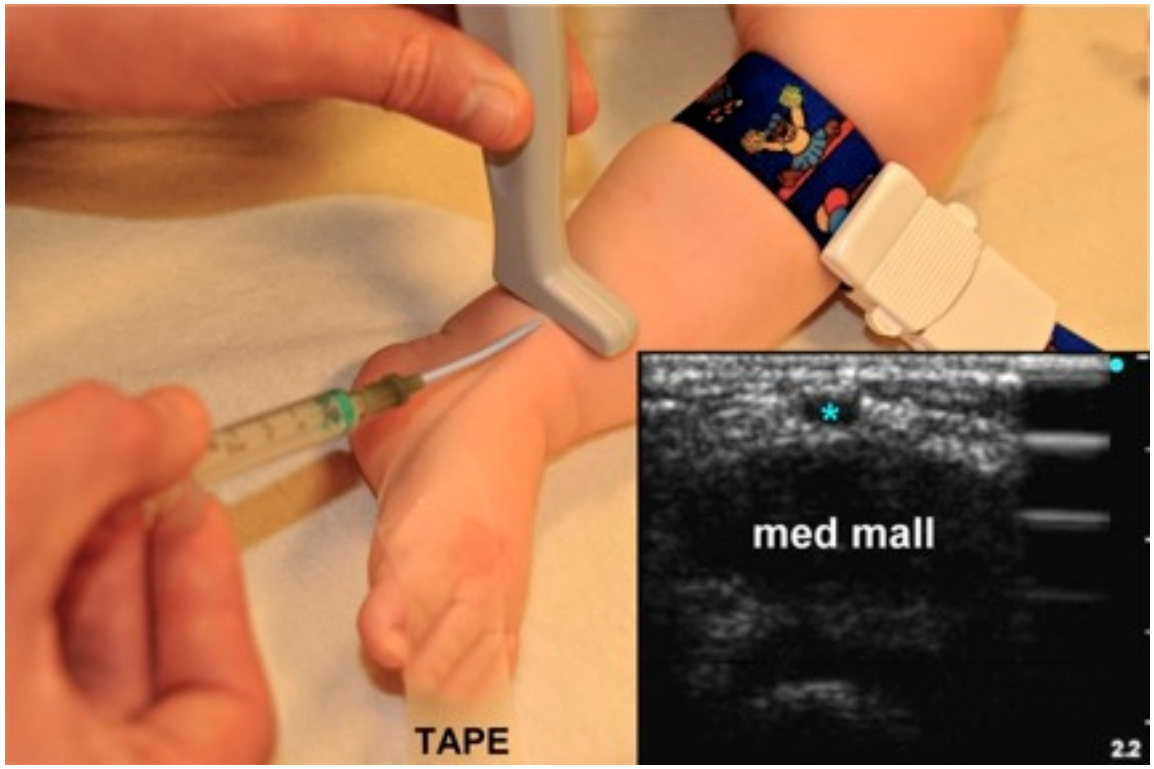

Devices for PVA ?

- *USG* - ! deep veins - USG puncture ok - insufficient cannulation ....

basilic vein antecubital fossa

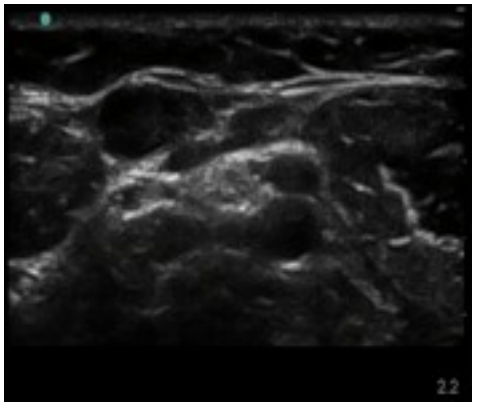

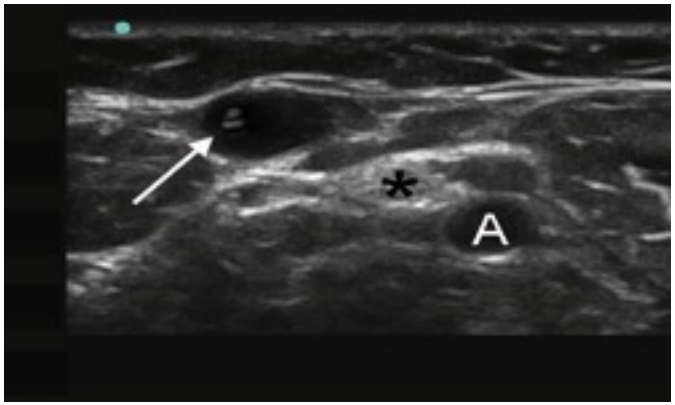

short catheters survival

time to dislodgment

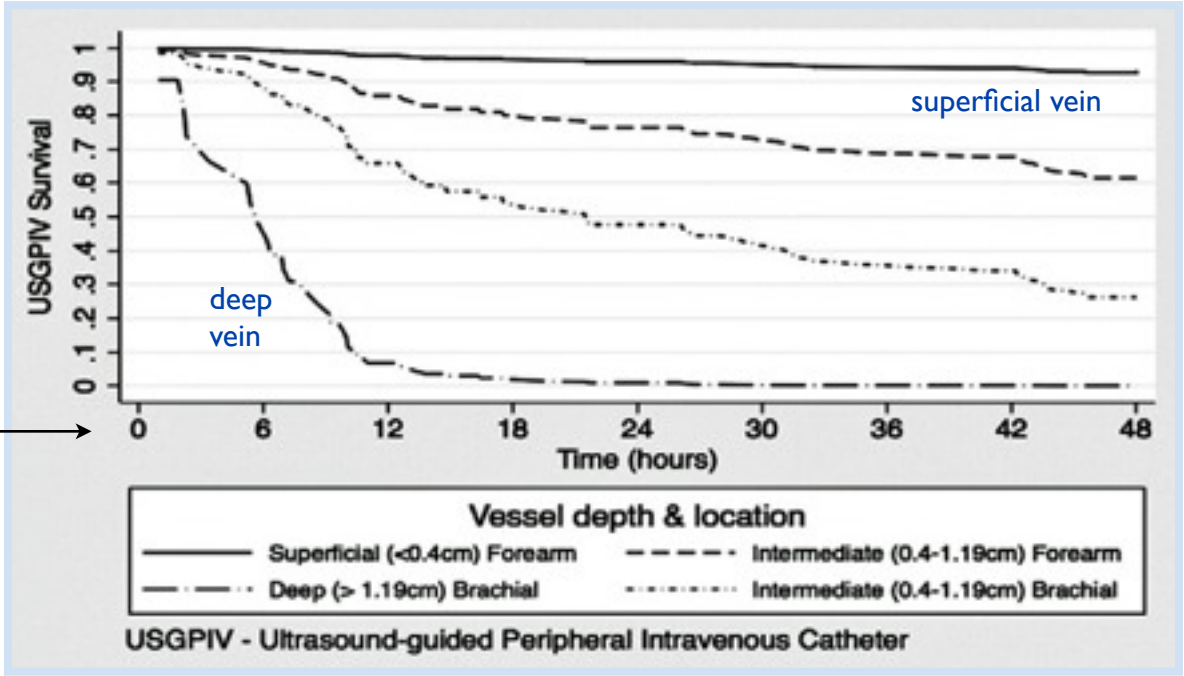

Long IV cannula or Mid-Line

PowerGlide - Bard

- 22-20-18 ga / 8 or 10cm
- quick insertion

Central Venous Access

- Difficult situations in children ? :
  - need to proceed under GA
  - as for adults: problems often unknown
  - the young child - infants & neonates
    - the equipment
    - the puncture

Lowering the age limit to proceed under LA

- think : « Picc Line »

Medical indications :
- neuromuscular pathologies
- severe chronic pulmonary infections
- ...
- ex: 5 y old healthy / 18 months old sick +++

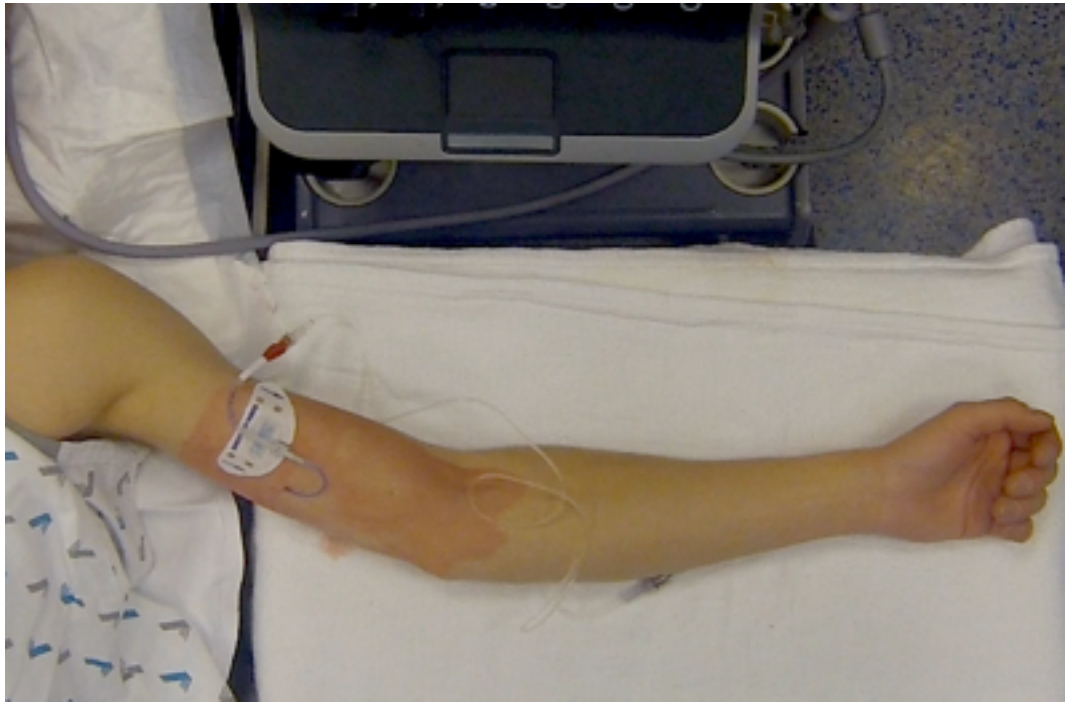

Picc Lines

- under GA
- LA alone
- Hypnosis + LA
- N2O + LA
- Midazolam + LA



Picc Lines

- technically not always easier than classic CVC
- our limit = 10kg / 1 year (picc 3 fr)
- ! vein puncture without success = vein lost

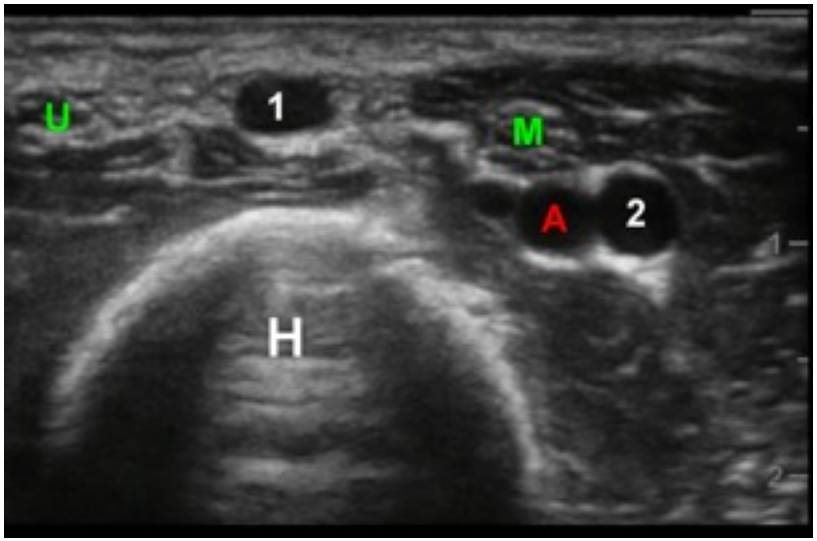

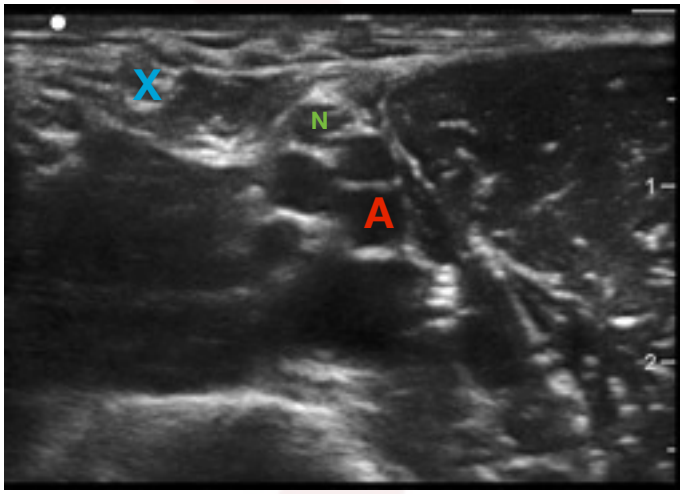

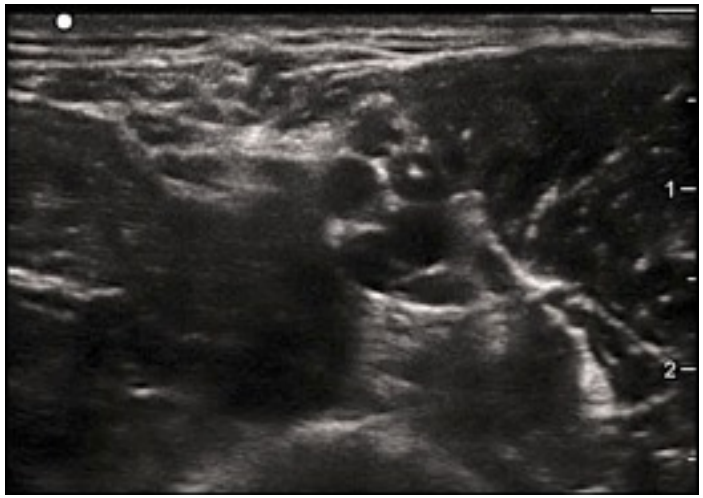

Central Venous Access

- Difficult situations in children ? :
  - need to proceed under GA
  - as for adults: problems often unknown
  - the young child - infants & neonates
    - the equipment
    - the puncture

under the skin

ULTRASOUND
=
huge benefit

CVA : the problem is often unknown

« detecting the difficult puncture BEFORE it gets difficult »

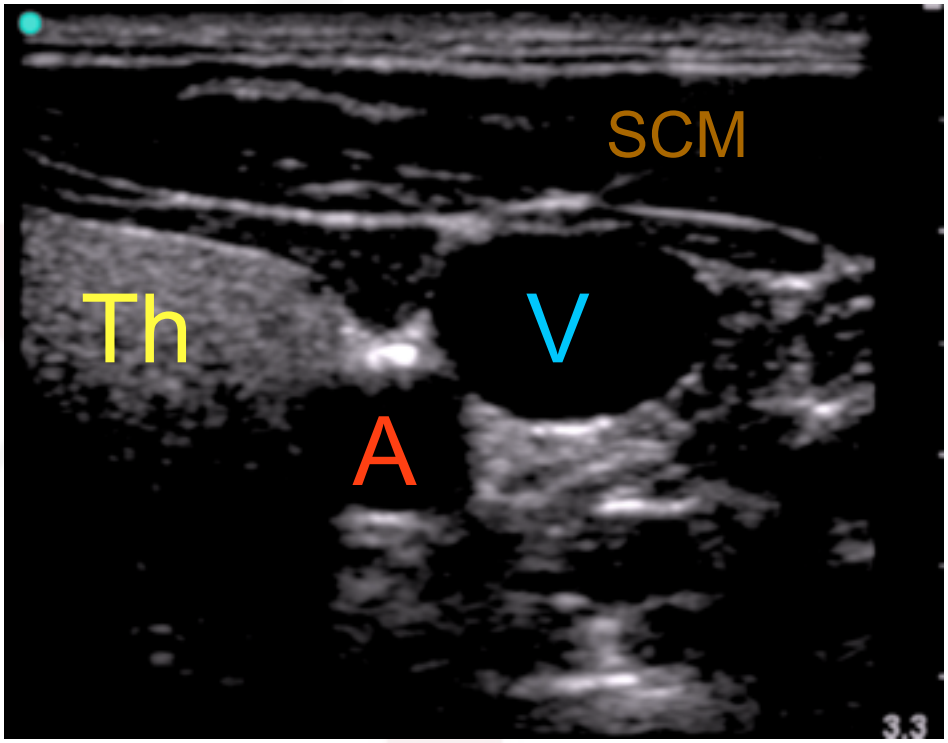

abnormal vein position

CVA : the problem is often unknown

« detecting the difficult puncture BEFORE it gets difficult »

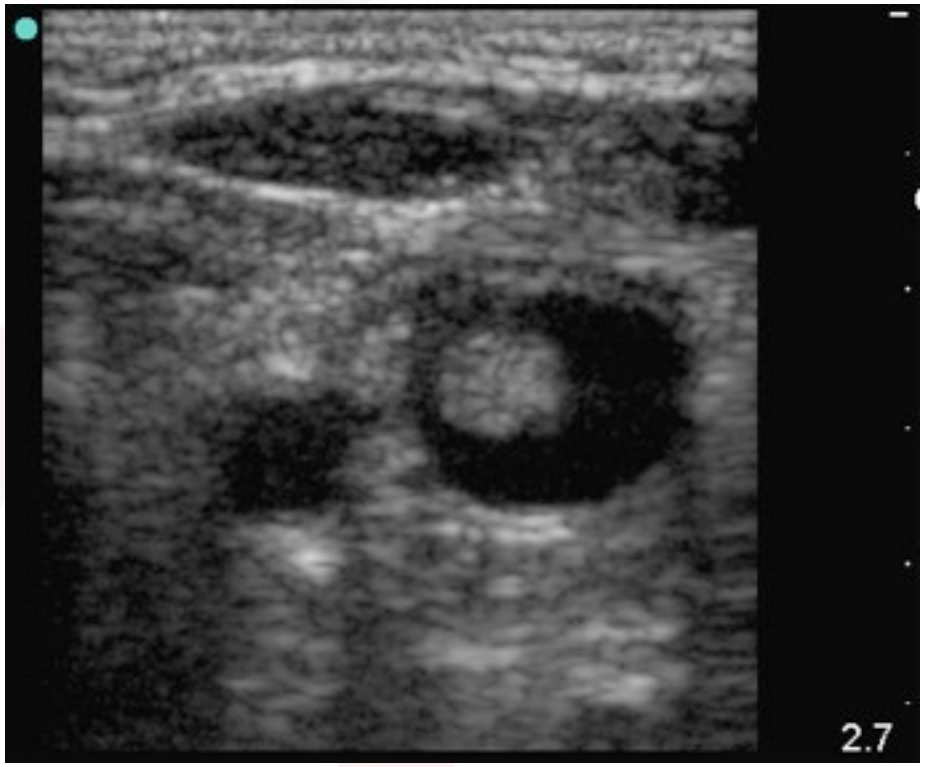

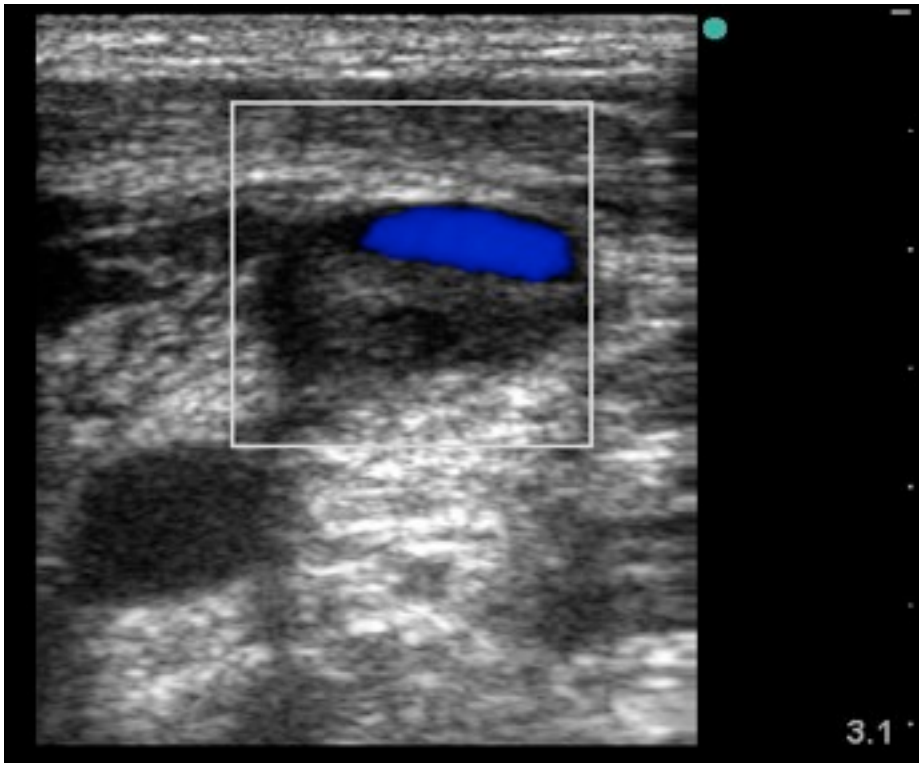

abnormal patency

Benefits of USG

avoid inadvertent arterial puncture
optimize the vein puncture & catheterization

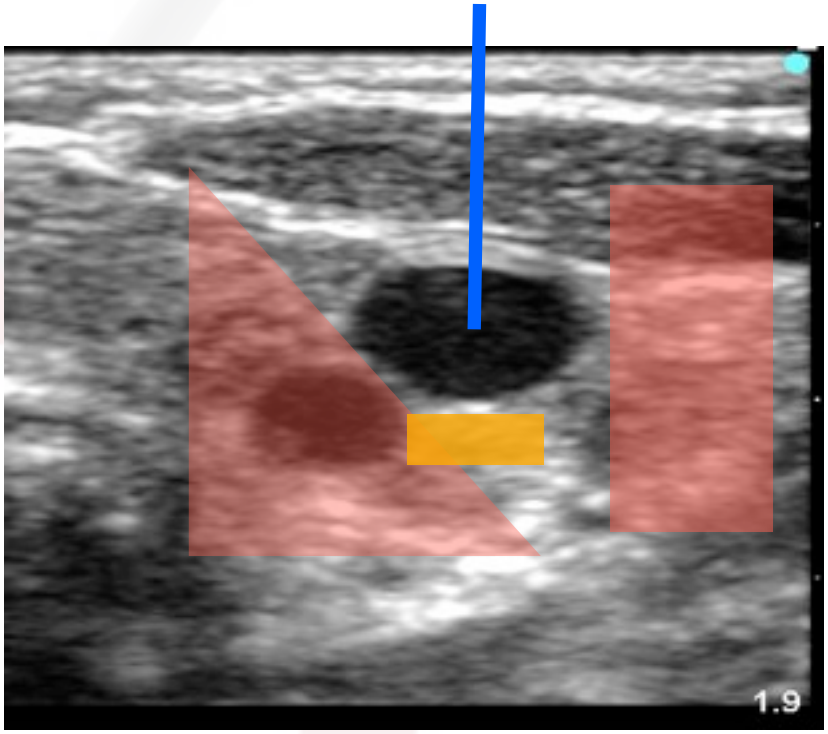

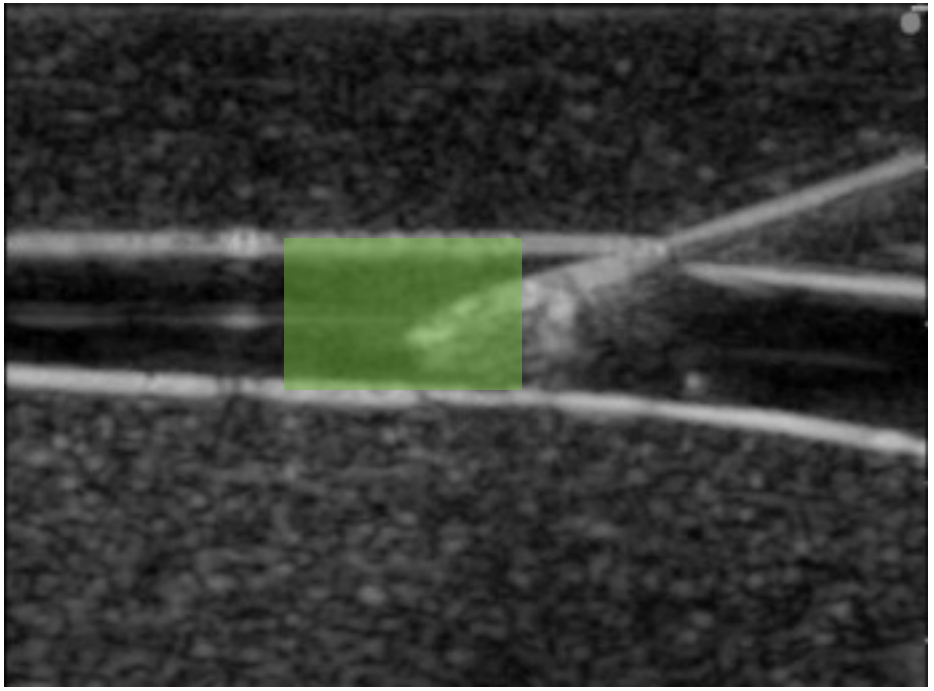

Overall Goal of USG in children:

reducing the Number of Attempts

⇔ Chance to success

(-25% success chance / attempt)

Incidence of complication

(high if > 3 attempts)

Risk of HD instability, hypothermia, ...

(procedure time = anesthesia time)

Other benefits of US

confirm correct GW migration before dilatation
detect possible early complication

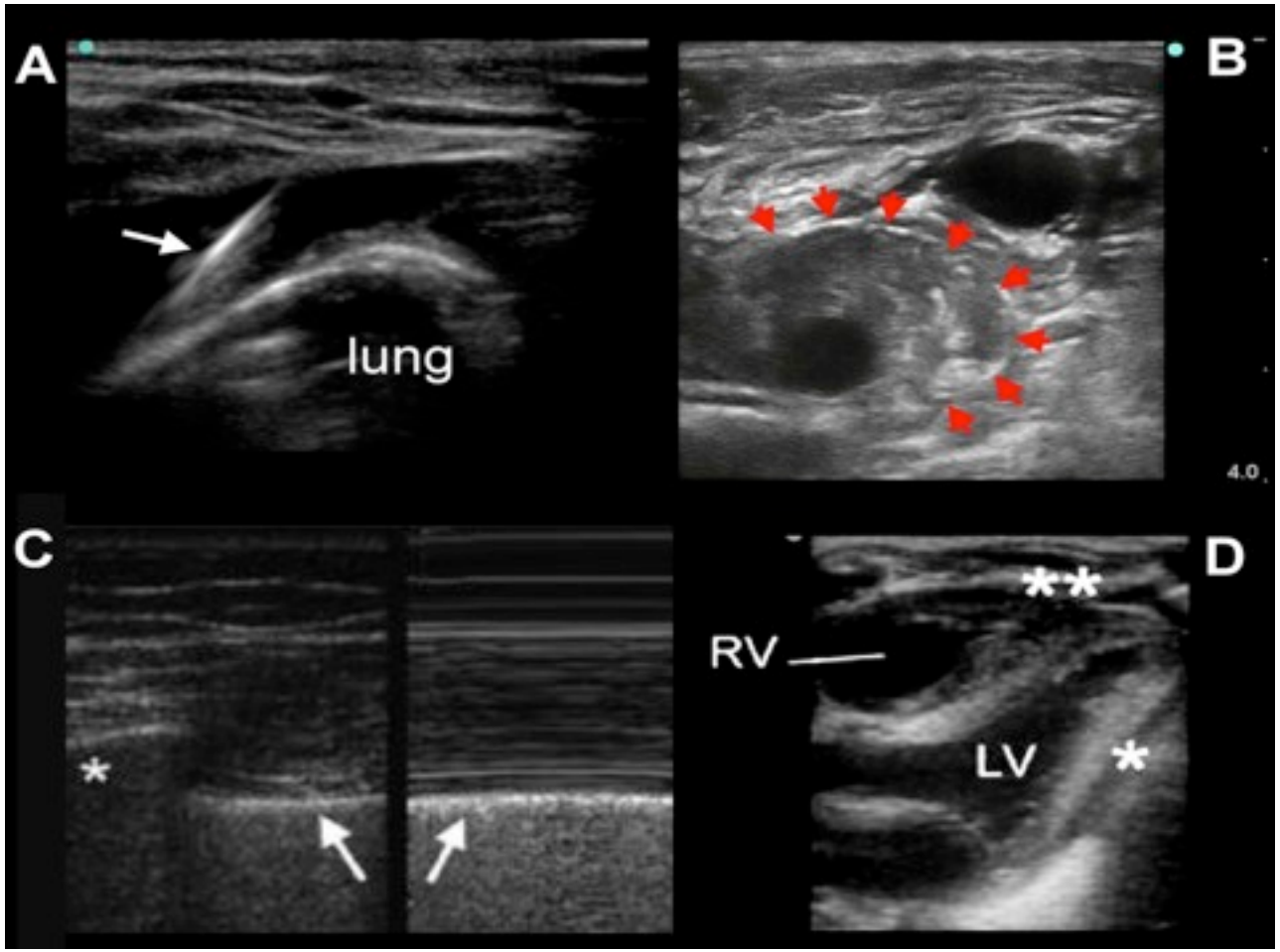

Recommendations

2002: Nice (National Institute for Clinical excellence) – UK

www.nice.org.uk

2012: ASA Task force on central venous access – USA

Anesthesiology 2012;116:539-73

2012: AS of Echocardiography & SCardioVx Anesth – USA

Anesth Analg 2012;114:46-72

2012: International EB recomm. on Vascular access – Int.

Int Care Medecine 2012; 38:1105-17

2014: SFAR Guidelines use of USG for vascular access - France

Anaesth Crit Care Med 2015; 34: 65-69

Recommendations

1) Prescreening - choosing the site of insertion
2) US guidance
3) Screening of the GW before dilation
4) US available to detect early complications

- IJV
- FV
- (SCV)
- Picc Lines
- PVA (if difficult)
- AL (if difficult)

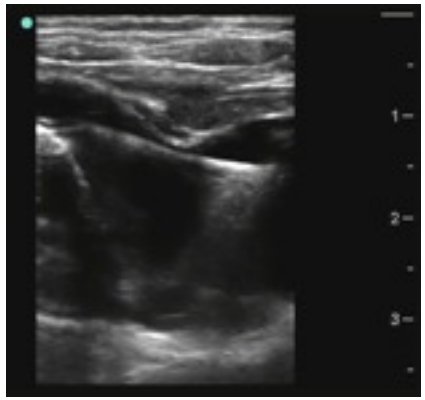

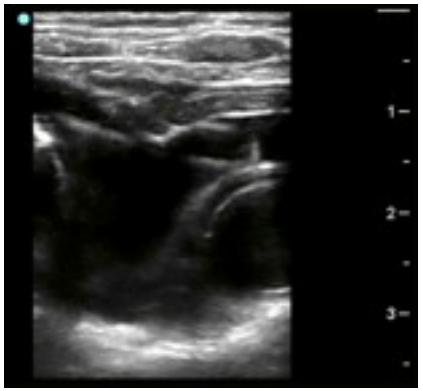

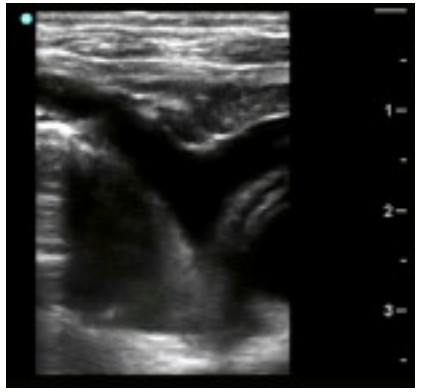

Central Venous Access

- Difficult situations in children ? :
  - need to proceed under GA
  - as for adults: problems often unknown
  - the young child - infants & neonates
    - the equipment
    - the puncture

Size: child vs probe size

* Having an adapted probe is mandatory

* Screening is better than nothing

  - position - patency - diameter
  - vein track vs arteries & lung

* if the probe is too large, OOP is easier

* using a part of the probe is possible

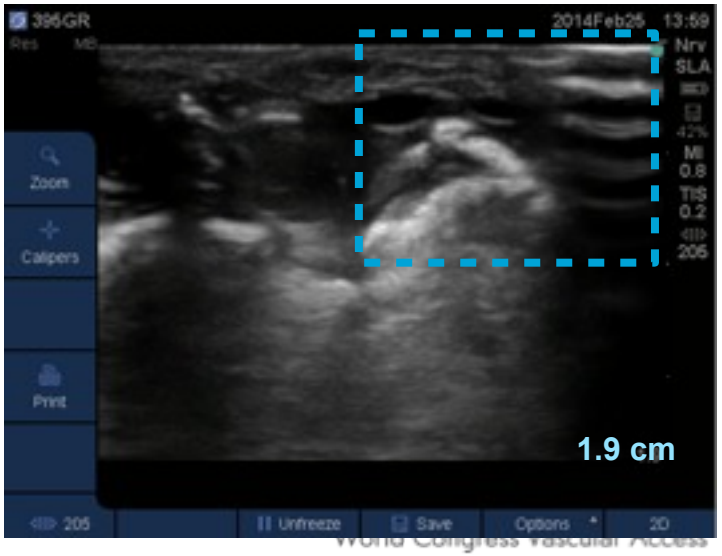

Size: vein vs needle & catheter

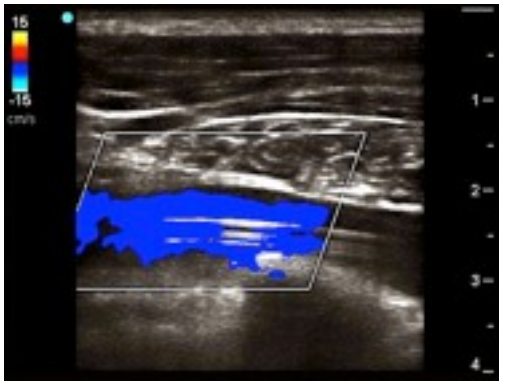

Age	vein	needle	1 lumen	2 lumens
preterm	<1–2 mm	0,72 mm 35 – 100%	0,64 mm 30 – 65%	1,40 mm 70 – 100%
term	2–4 mm	0,72–0,81	0,81 mm	1,40 mm
5 years	3–7 mm	0,81–1,02	1,02 mm	1,70 mm
10 years	5–10 mm	0,81–1,02 8 – 20%	1,29 mm 12 – 25%	1,70 mm 15 – 35%

(Arrow)

Catheters

	< 1,5 kg	newborn	6 m - 4 y	4 - 10 y	> 10 y
single lumen CVC	2 F (22 ga)	3 F (20 ga)	3 F (20 ga)	4 F (18 ga)	5 F (16 ga)
double lumen CVC	/ *	4 F	4 F	5 F	7 F
PICC	1 F (28 ga)	2 F (23 ga)	3 F (vein > 3mm)	4 F (vein > 4 mm)	5 F (vein > 5 mm)
Umbilical catheters	3,5 F	5 F	/	/	/

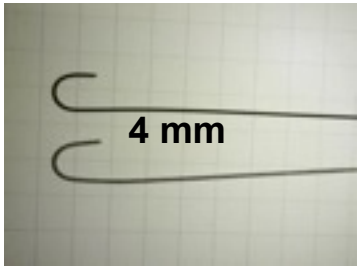

Guidwires

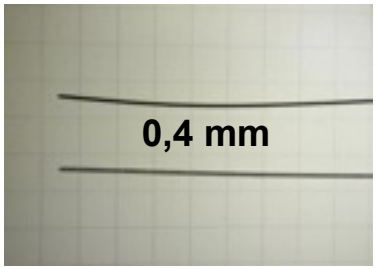

5 mm vein

2 mm vein

Dilation

From 'damaged' introducer to 'kinked' guidewire





- gentle pressure
- in the same track as the needle
- in/out movement detect guidewire kinking
- progressive dilatation with peripheral cannula's

Central Venous Access

- Difficult situations in children ? :
  - need to proceed under GA
  - as for adults: problems often unknown
  - the young child - infants & neonates
    - the equipment
    - the puncture

Access to the Femoral Vein

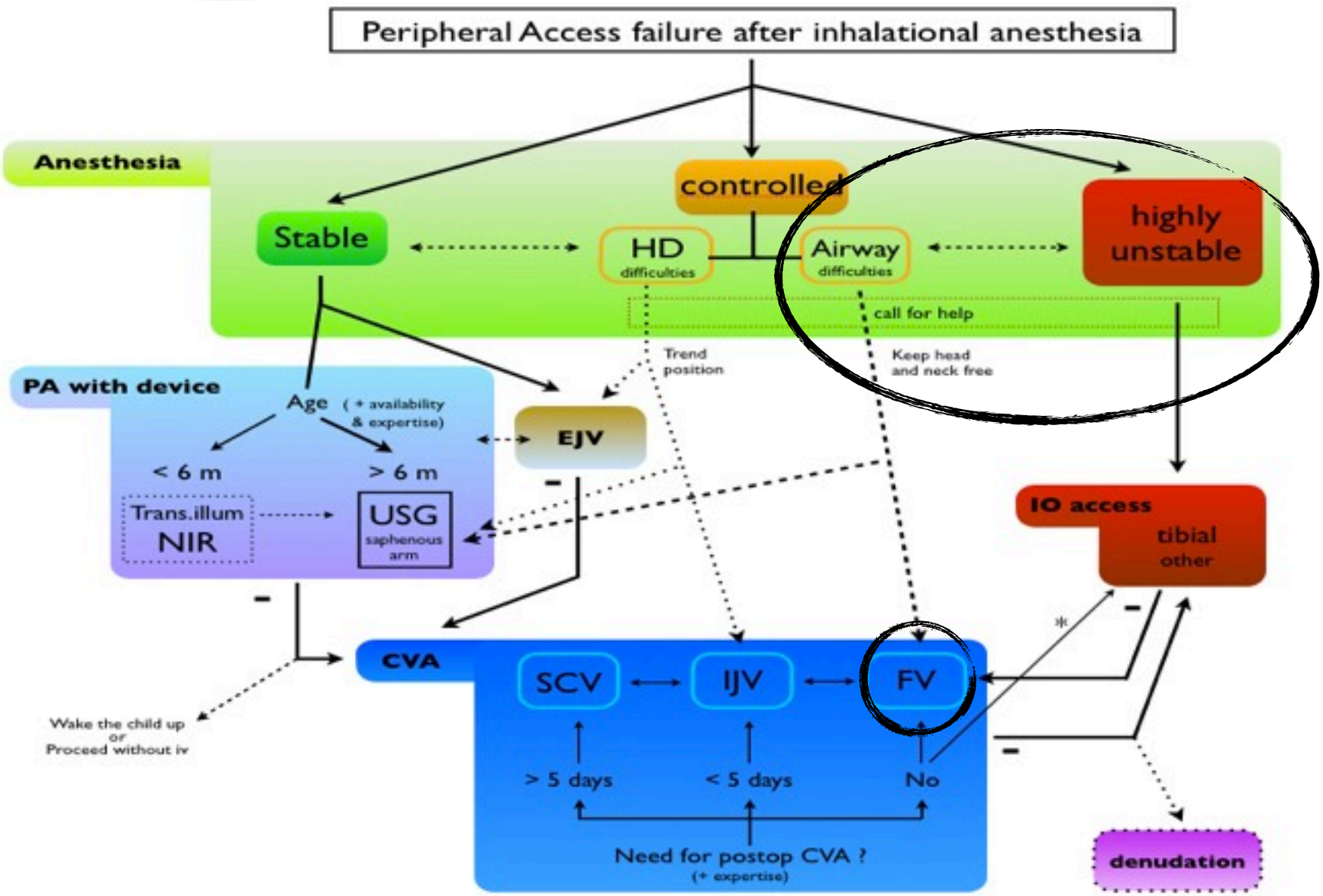

the Femoral Vein

- low US image quality *
- optimal leg position (arterial overlap)
- check ilio-femoral patency

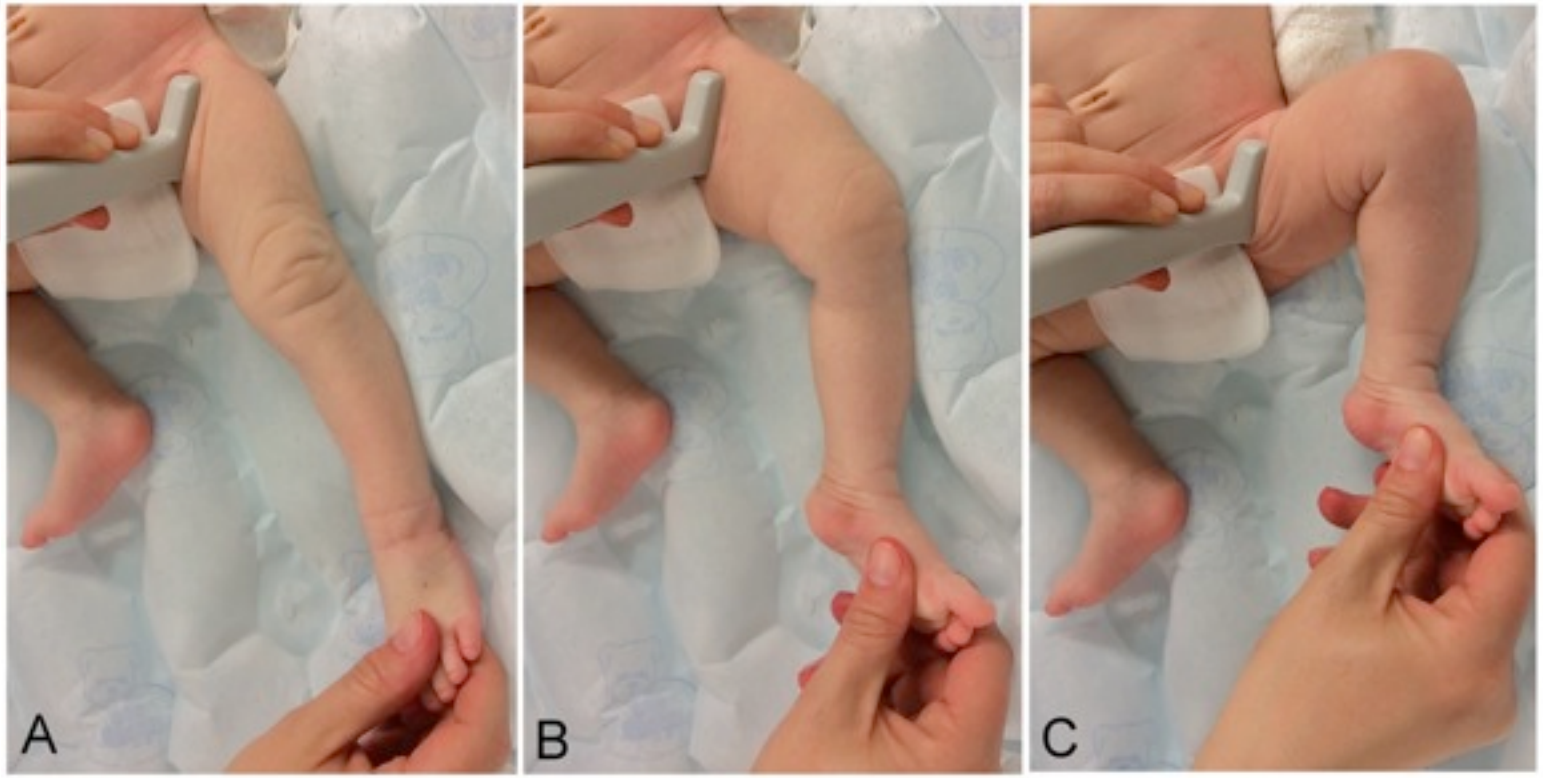

the Femoral Vein

- frequent transfixion
- reduce arterial puncture
- track guidewire before dilation

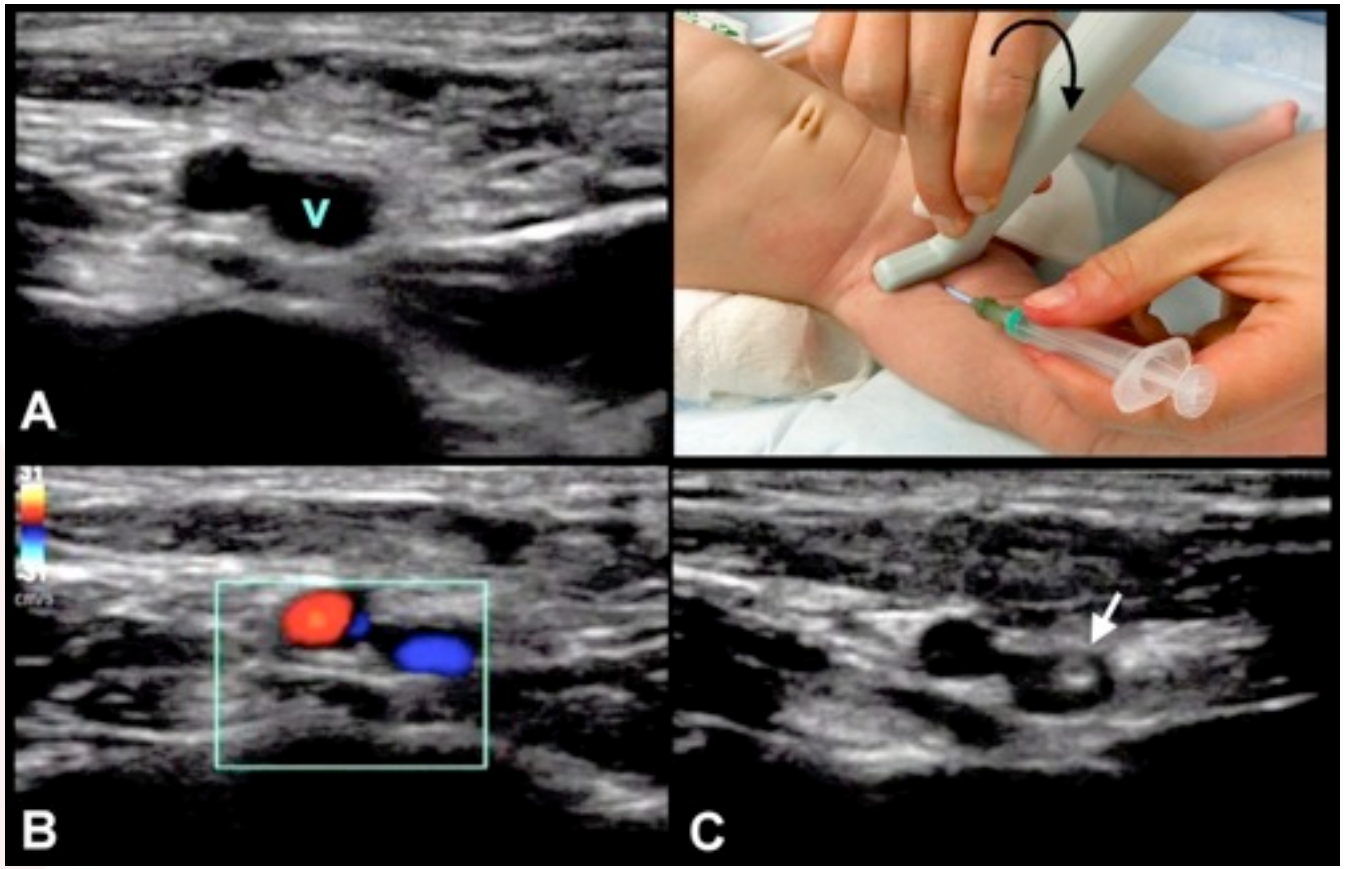

Access to the Internal jugular Vein

- small children have no neck



- the vein is small and highly mobile
- the needle is big, the J-shaped GW is huge in neonates

22ga



0.18" J guidewire

Morita M. Anesth Analg 2009

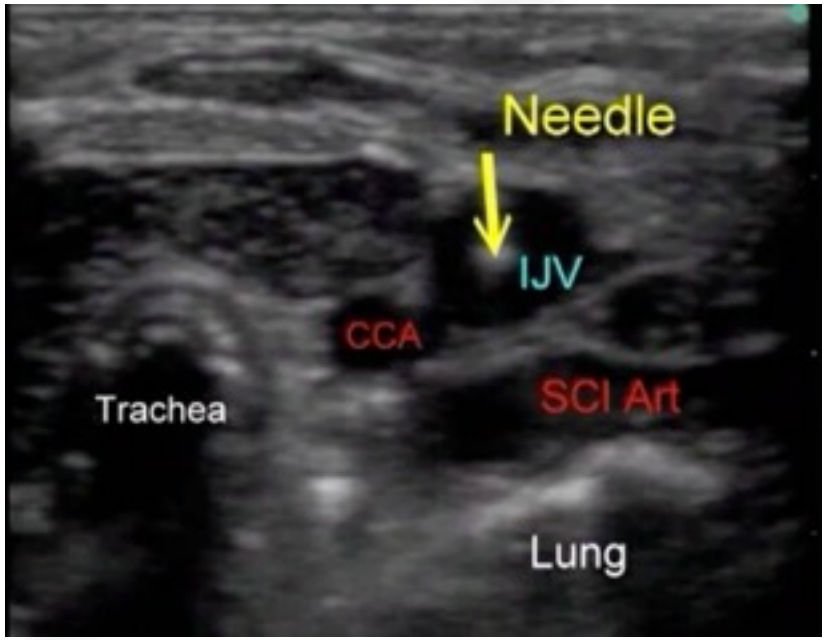

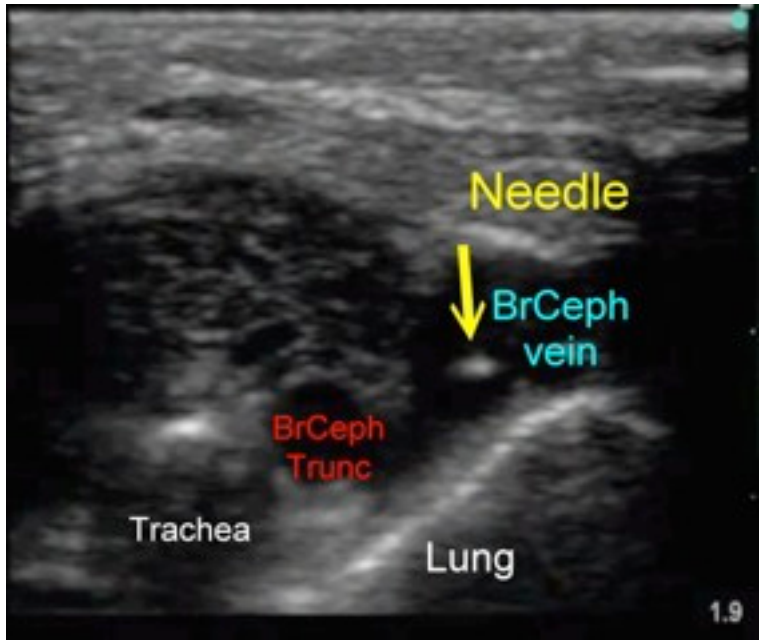

- Subclavian vessels are « extrathoracique »
  - accidental arterial puncture : not always the CA (SClav A)

- Lung top protrudes above the clavicle
  - pneumothorax & anterior approach IJV

Guidewire insertion

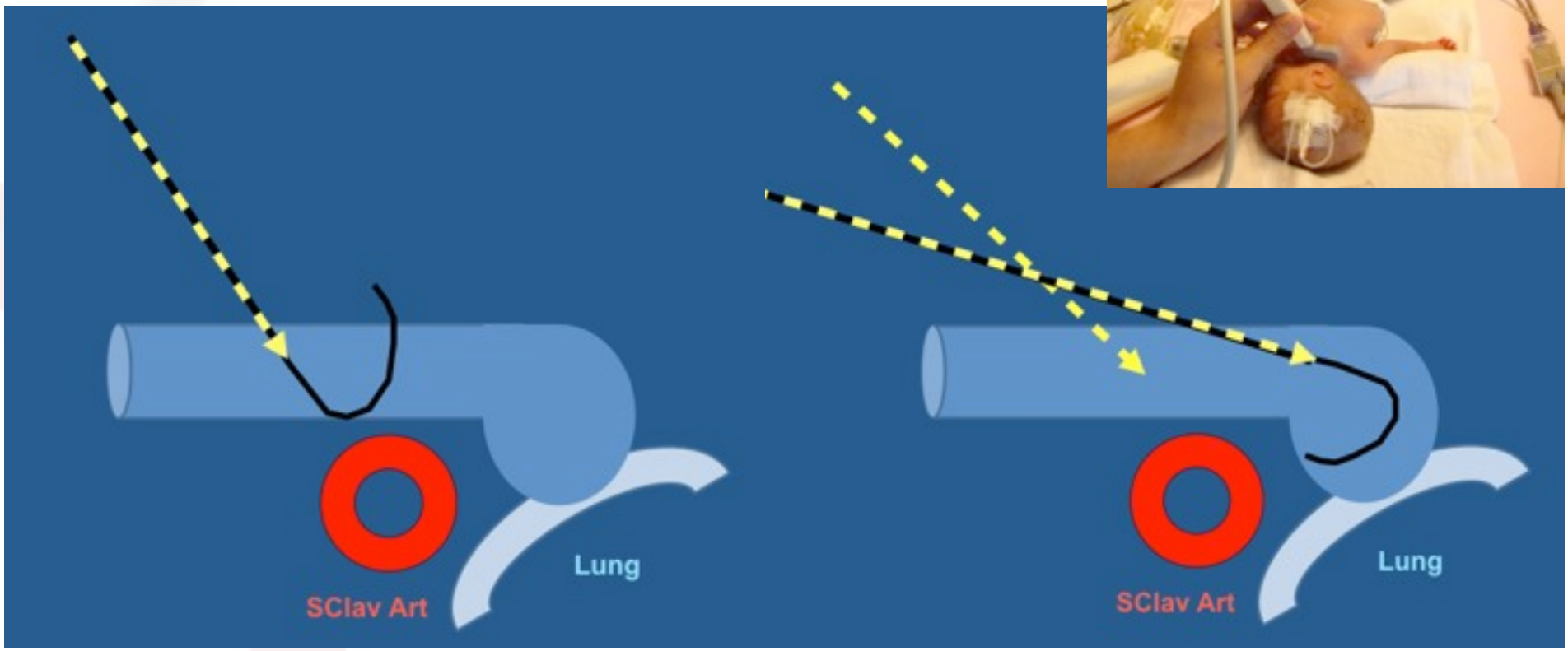

Guidewire insertion

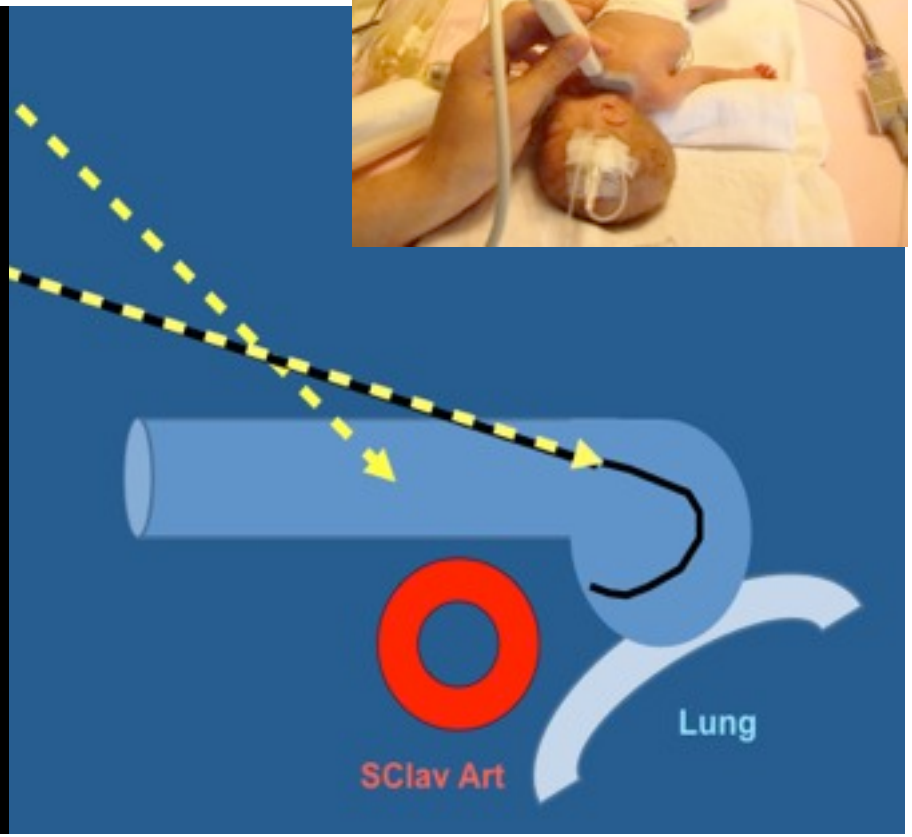

« Peri-clavicular » Accesses

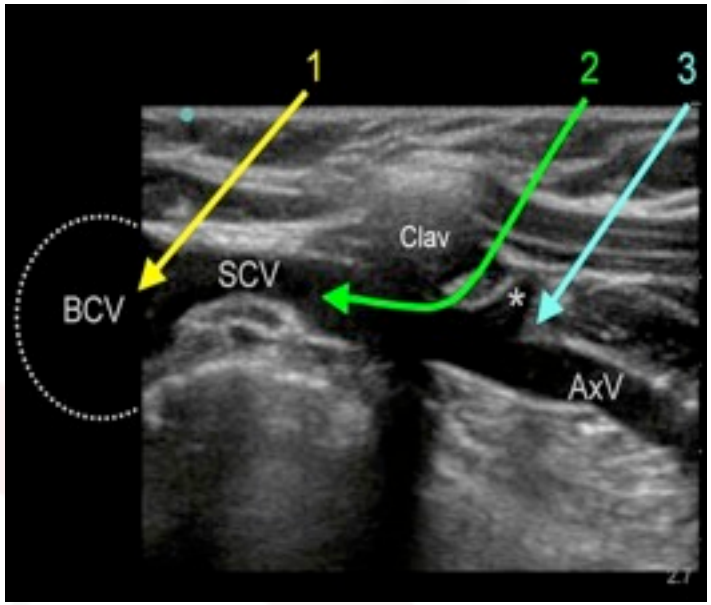

Approach - Targeted vein	Guidance	Age categories	USG Technique	Advantages	Disadvantages
Supraclavicular - Brachiocephalic vein	US	all	LAX - IP	- large & open vein - easy puncture	- central approach - exit site - ! brachial plexus
Infraclavicular - Subclavian vein	US / LM	all *	LAX - IP LAX - OOP *	- open vein - safe progression - exit site	- shadow clavicle - orientation children/ adolescents *
Transpectoral - Axillary vein	US	(children) adolescents	SAX - OOP LAX - IP	- exit site - comfort	- depth - compressibility vein - proximity pleura

TABLE 5: Comparison between three different peri-clavicular approaches for CVC placement in children. US: ultrasound, LM: landmark. *: the US-guided infraclavicular approach of the subclavian can be more difficult in older children (visualization of the vein, 3-D orientation, initial OOP approach).

« Peri-clavicular » Accesses

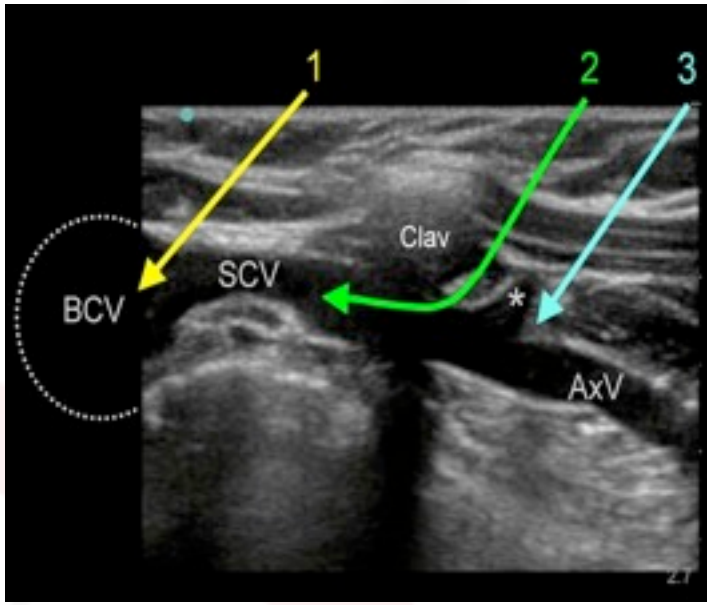

Approach - Targeted vein	Guidance	Age categories	USG Technique	Advantages	Disadvantages
Supraclavicular - Brachiocephalic vein	US	all	LAX - IP	- large & open vein - easy puncture	- central approach - exit site - ! brachial plexus
Infraclavicular - Subclavian vein	US / LM	all *	LAX - IP LAX - OOP *	- open vein - safe progression - exit site	- shadow clavicle - orientation children/ adolescents *
Transpectoral - Axillary vein	US	(children) adolescents	SAX - OOP LAX - IP	- exit site - comfort	- depth - compressibility vein - proximity pleura

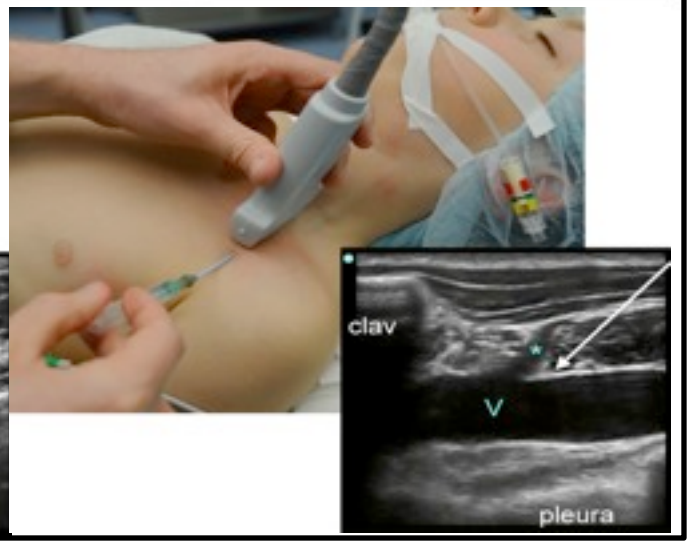

« Peri-clavicular » Accesses

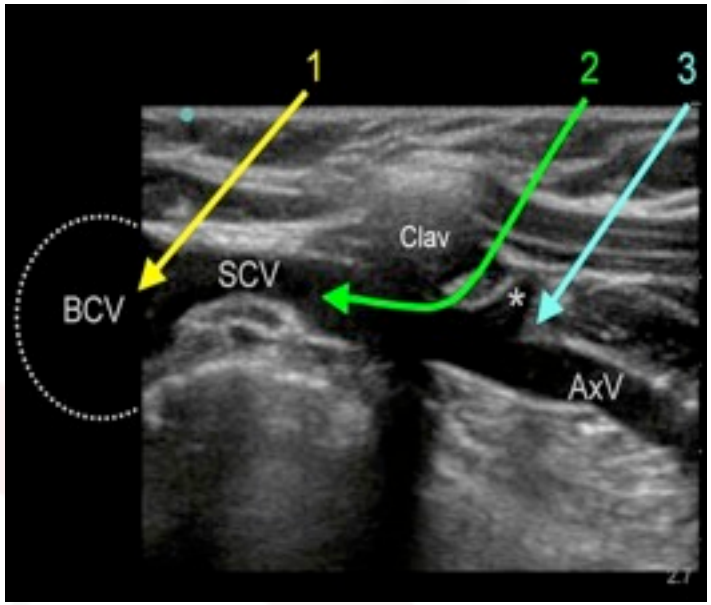

Approach - Targeted vein	Guidance	Age categories	USG Technique	Advantages	Disadvantages
Supraclavicular - Brachiocephalic vein	US	all	LAX - IP	- large & open vein - easy puncture	- central approach - exit site - ! brachial plexus
Infraclavicular - Subclavian vein	US / LM	all *	LAX - IP LAX - OOP *	- open vein - safe progression - exit site	- shadow clavicle - orientation children/ adolescents *

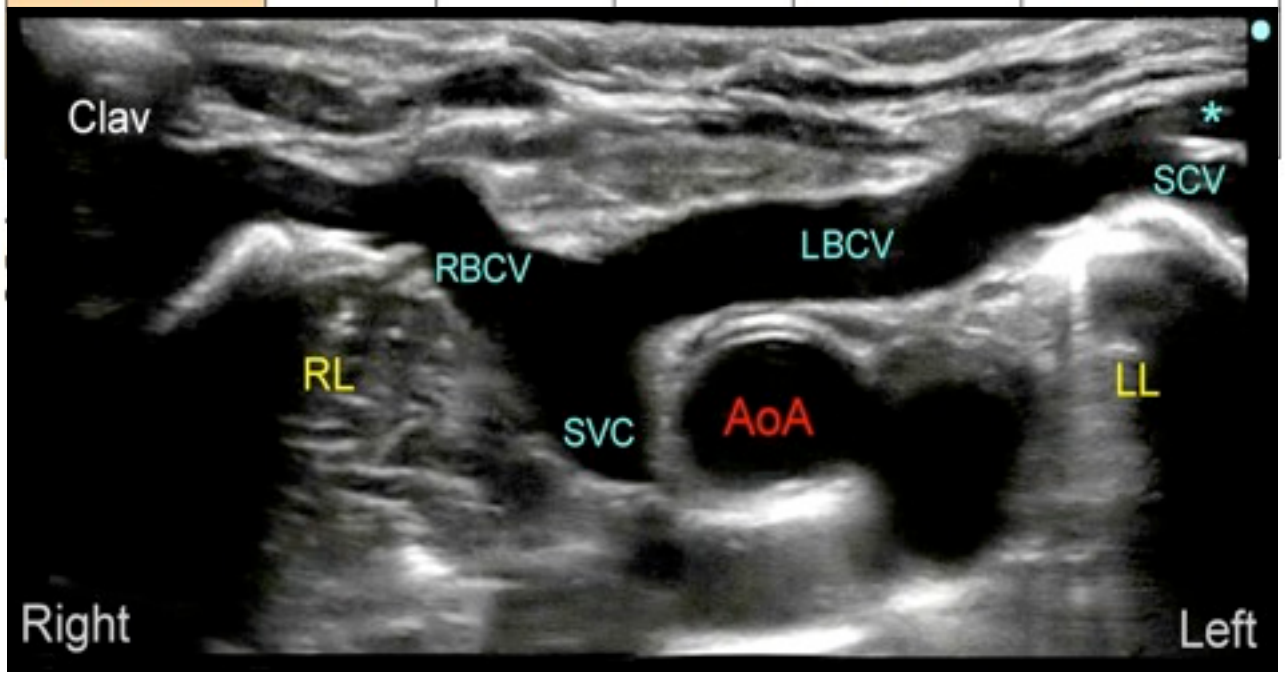

SCV & BCV

are

« open » & « fixed »

- infra & supra- clavicular approches described
- nice in-plane approach

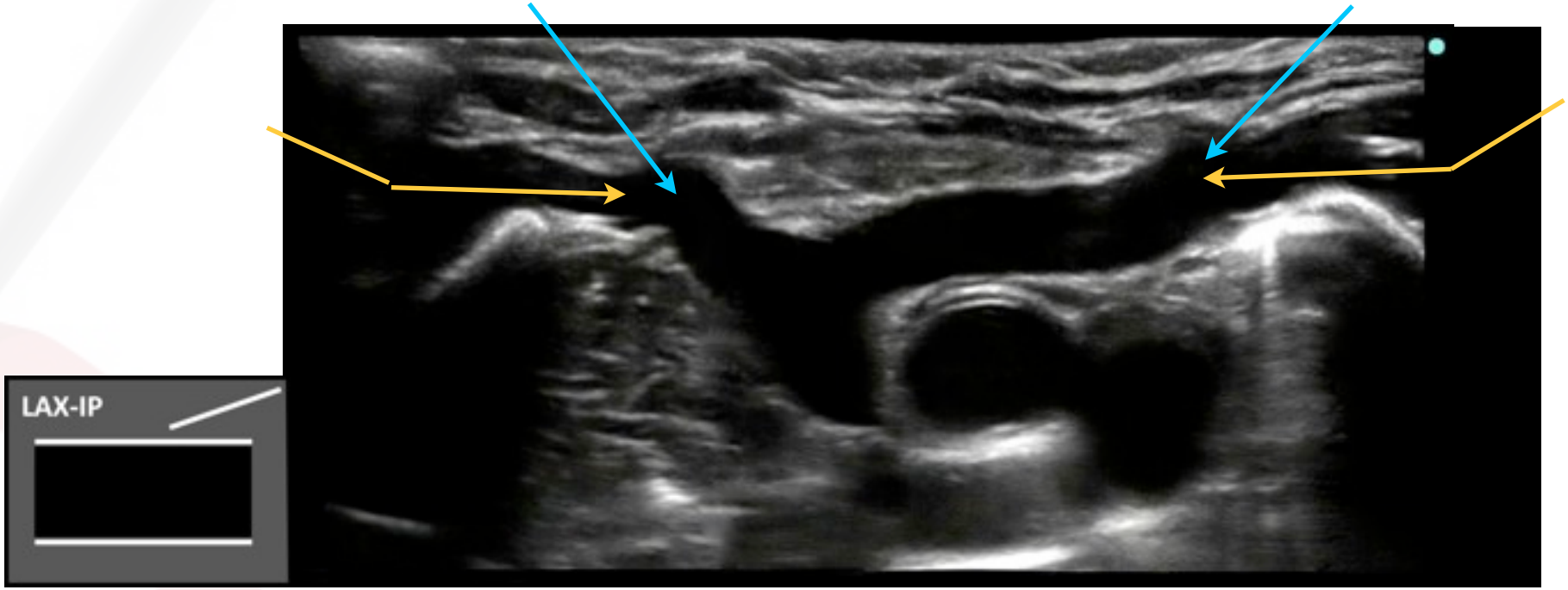

- easier guide wire insertion

- Supraclavicular access of the BCV

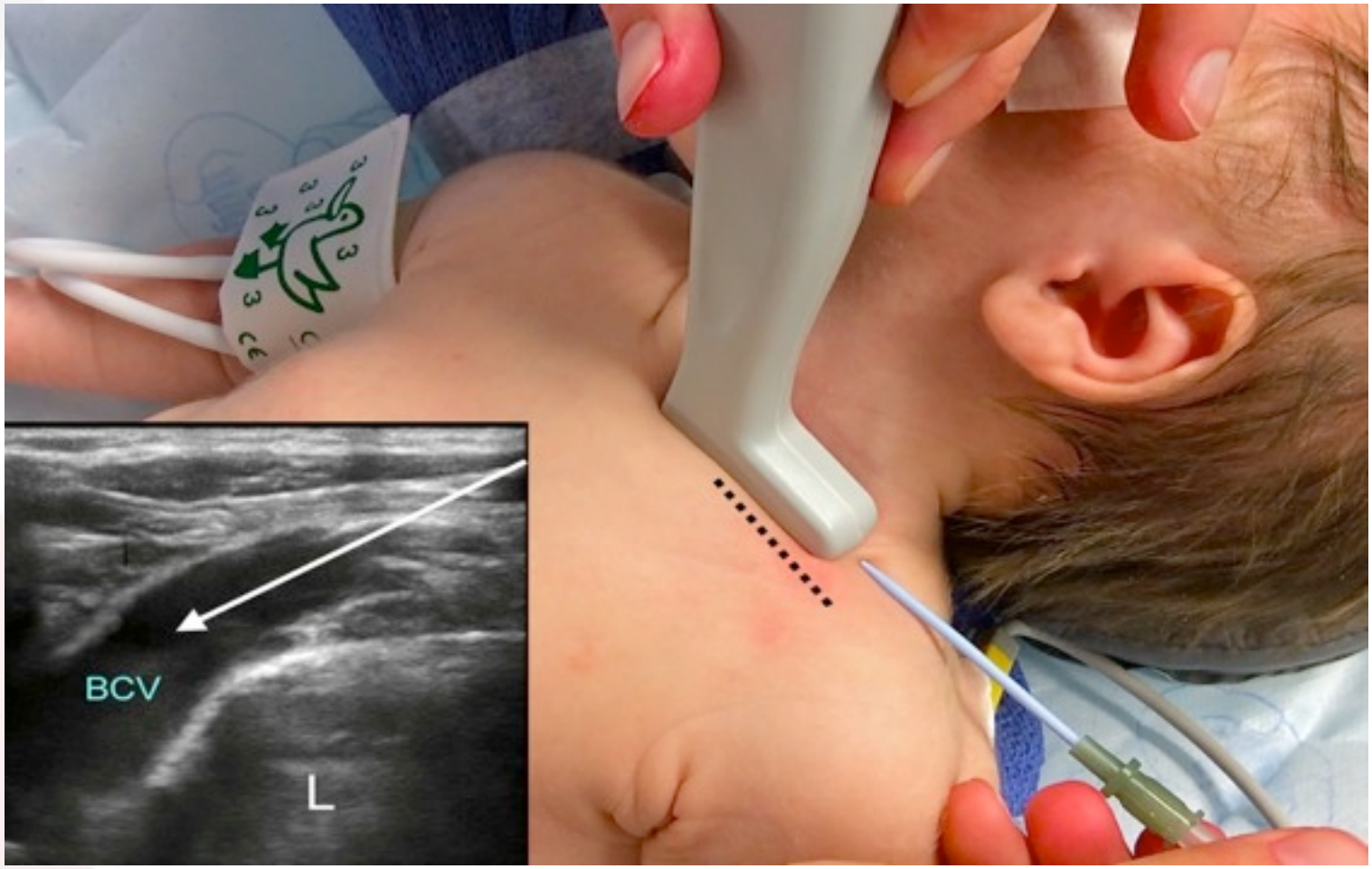

- Infraclavicular access of the SCV

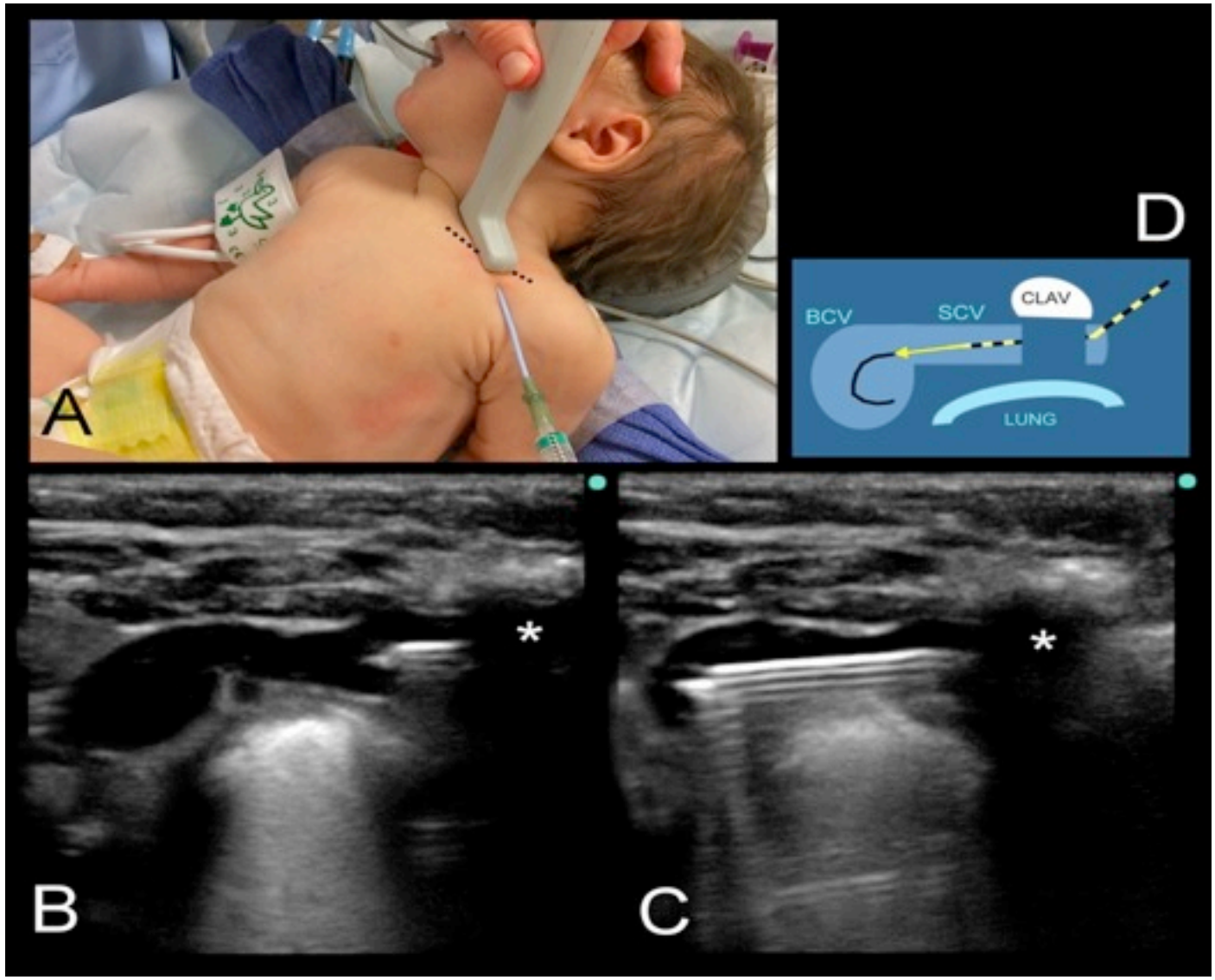

More and more used in low weight infants as alternative for IJVs

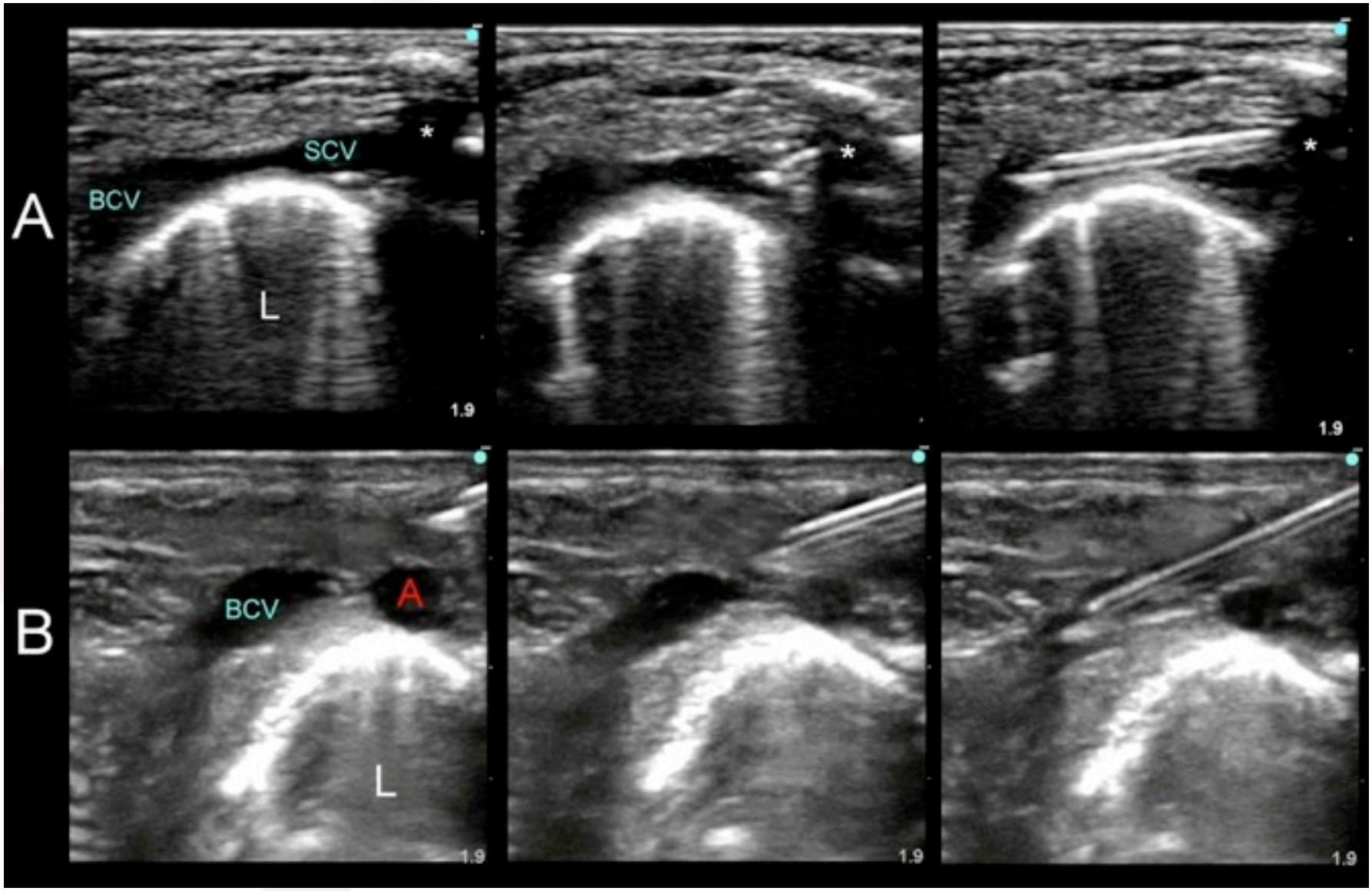

800 gr

example of SCV access

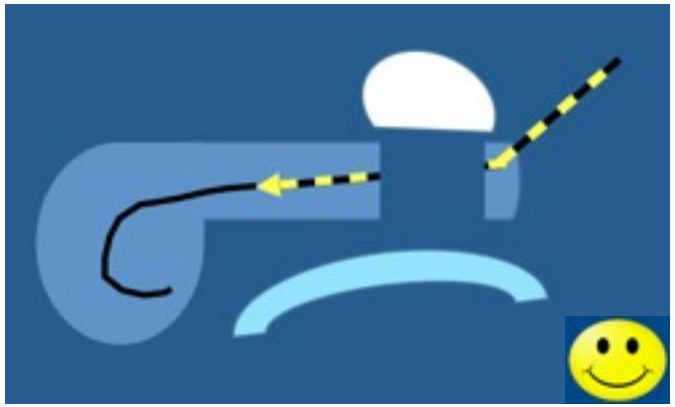

Guidewire insertion facilitated by placing the needle tip into the BCV

the vein do not collapse ...

right SCV
1 day old

• VA in Children

- remains challenging
- plan B to get a first access should be available for stable and urgent situations
- ultrasonography & IO devices are useful
- technological progresses will help us
- … but manual skills remains important

Learning more...

Book eBook eChapter

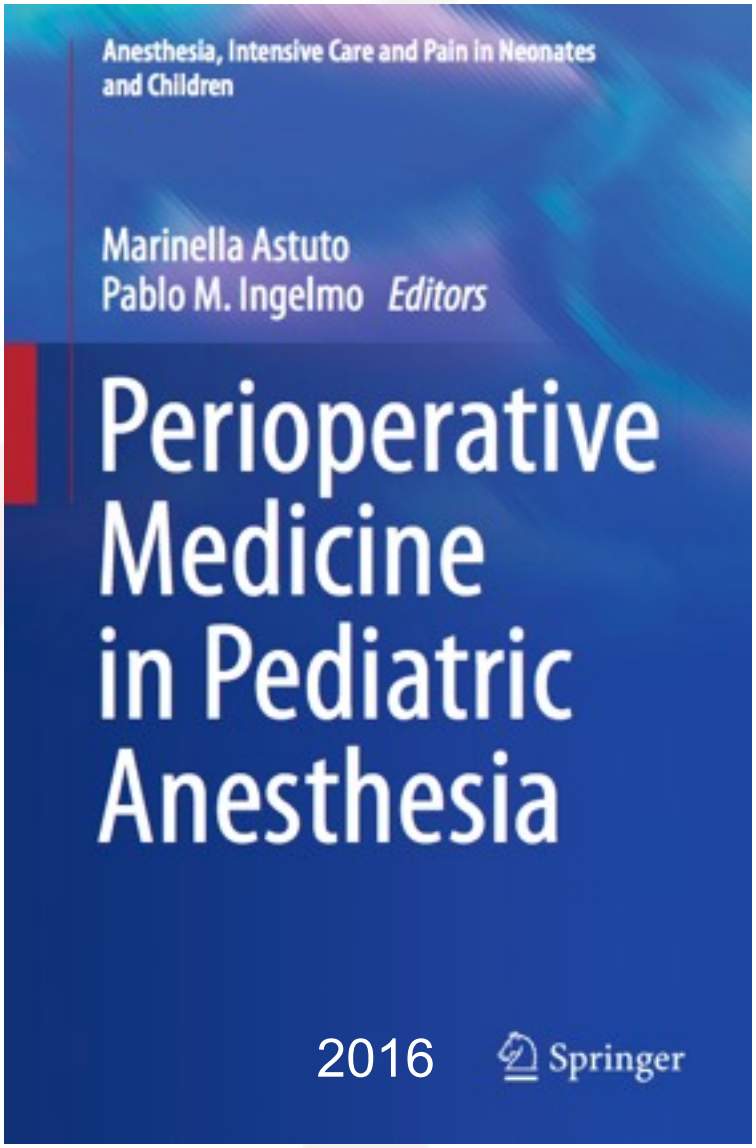

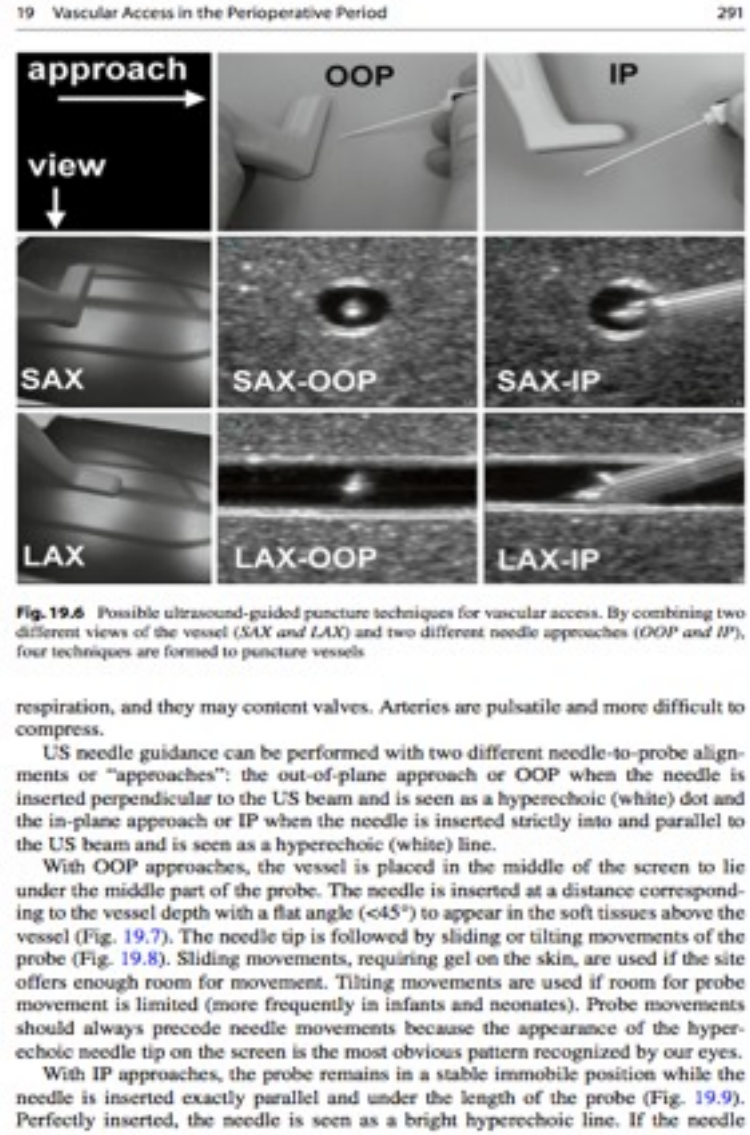

19 Vascular Access in the Perioperative Period 291

Fig. 19.6 Possible ultrasound-guided puncture techniques for vascular access. By combining two different views of the vessel (*SAX and LAX*) and two different needle approaches (*OOP and IP*), four techniques are formed to puncture vessels

respiration, and they may content valves. Arteries are pulsatile and more difficult to compress.

US needle guidance can be performed with two different needle-to-probe alignments or "approaches": the out-of-plane approach or OOP when the needle is inserted perpendicular to the US beam and is seen as a hyperechoic (white) dot and the in-plane approach or IP when the needle is inserted strictly into and parallel to the US beam and is seen as a hyperechoic (white) line.

With OOP approaches, the vessel is placed in the middle of the screen to lie under the middle part of the probe. The needle is inserted at a distance corresponding to the vessel depth with a flat angle (<45°) to appear in the soft tissues above the vessel (Fig. 19.7). The needle tip is followed by sliding or tilting movements of the probe (Fig. 19.8). Sliding movements, requiring gel on the skin, are used if the site offers enough room for movement. Tilting movements are used if room for probe movement is limited (more frequently in infants and neonates). Probe movements should always precede needle movements because the appearance of the hyperechoic needle tip on the screen is the most obvious pattern recognized by our eyes.

With IP approaches, the probe remains in a stable immobile position while the needle is inserted exactly parallel and under the length of the probe (Fig. 19.9). Perfectly inserted, the needle is seen as a bright hyperechoic line. If the needle

57 pages

Vascular Access in Children

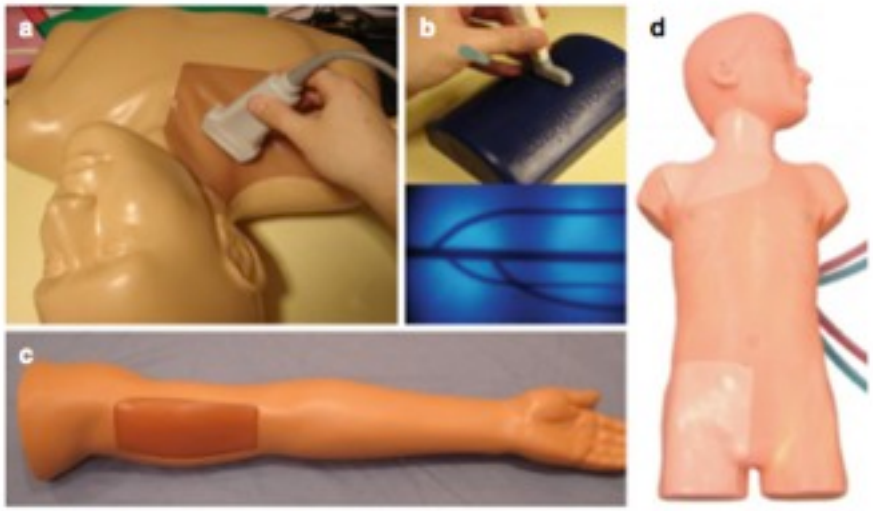

Fig. 19.10 Different gel models used for pediatric vascular access training sessions. (a) "Head and torso," (b) "pediatric vessels," and (c) "PICC insertion arm" from Blue Phantom® and (d) "vascular access child" from Simulab®

Fig. 19.11 Sterility and ergonomy. (a) Long sterile drape and probe covers ensure maximal barrier precautions. (b) Hands and US screen are aligned in front of the operator to facilitate handling

Fig. 19.38 Insertion of a peripherally inserted central catheter on the left arm of a child. (a) Sterile dressing and positioning during a USG puncture at mid-arm level (SAX–OOP technique). (b) Insertion of the dilator and introducer over the guide wire. (c) Insertion of the PICC in the peel-away introducer. (d) Fixation by a suture-free StatLock® above the antecubital fossa

19.4.2.5 Catheter Tip Positioning

A non-central placement of the PICC increases the risk of mechanical and thrombotic complications. It is therefore advised to avoid blind insertions and to use either ECG guidance or fluoroscopy. The ideal position is the cavo-atrial junction when the arm is in adduction with the elbow slightly flexed. Fluoroscopy seems to be the easiest and most reliable and versatile tool because it shows the cavo-atrial junction with precision but also helps to direct the PICC from the arm (using phlebography) to the SVC (Fig. 19.39). Irradiation should however be reduced as much as possible in children by using adapted doses and short pulsed emission of X-ray and by closing the diaphragm.

19.4.3 Fixation and Maintenance

PICCs are fixed by a suture-free securing device (StatLock®, BARD) and covered by a transparent dressing. To increase comfort, the fixation should not reach the antecubital fossa and can therefore be placed above the insertion point (Fig. 19.38d). The dressing has to be changed every week and the catheter flushed with 10 ml of

Intraosseous Access
Courses

Teleflex®

United States | Worldwide

Search ... SEARCH Advanced...

Home | About Us | Investors | Brands | Product Areas | OEM Division | Services | Careers | Contact

Home » United States » ARROW® EZ-IO® Education

Clinical Education Resources
ARROW® EZ-IO® Intraosseous Vascular Access System

Online Education – Clinical Principles, Quiz and Certificate - View

View the most comprehensive online resource for ARROW® EZ-IO® Vascular Access education, complete a brief quiz and receive a certificate for successful completion.

Science and Fundamentals of Intraosseous Vascular Access 2013 2nd Edition - View

Download the most comprehensive and detailed document describing virtually every practical aspect of intraosseous (IO) access: IO anatomy and physiology, basic and clinical science supporting IO access, insertion sites and techniques, indications, contraindications and warnings, complications, frequently-asked questions...and so much more.

Intraosseous Vascular Access Bibliography - View

Download a comprehensive bibliography of articles describing intraosseous access (regardless of device type or brand name), organized in categories including pharmacokinetics, clinical studies, case studies, guidelines, intraosseous devices, pediatrics and complications.

Erasmus MC
Universitair Medisch Centrum Rotterdam

Clinical and Medical Affairs **Procedural Lab Programs - Europe, Middle East and Africa**



Pediatric Vascular Access Courses

Euroanaesthesia 2017
THE EUROPEAN ANAESTHESIOLOGY CONGRESS
GENEVA 03-05 JUNE

CC	PAEDC Pre-Congress Course	Friday, 2 June 2017 09:00 – 18:00	**Ultrasound guided central venous access in neonates, infants and children** **IMPORTANT NOTICE: access is limited to pre-registered delegates	Hall 1 - Room 1

Pre-registration is required and attendance is limited to 48 participants.

This course will provide literature update and practical information on new technologies, devices and techniques to achieving a successful vascular access in children. Participants will learn how to use ultrasound to improve success rates and patient care, preventing or treating short and long term complications, when central, peripheral, and peripherally inserted central lines catheters, arterial lines and intraosseum needles are inserted.

By the end of this course attendees will be able to:

- properly operate a ultrasound machine and make adjustments to obtain adequate image quality,
- acquire ultrasound images for examination of the vascular structures,
- adequately apply the use of ultrasound to facilitate the intravascular placement of catheters
- acquire the decision-making process for the correct choice of device and procedure for neonates and children.

Tutors will cover the basics of ultrasound and ultrasound-guided line placements, with specific focus on paediatric anatomy, dedicated devices and procedures for children. Areas covered will include jugular, femoral, subclavian venous access and arm vein access. An overview on the immediate and long term management on children with vascular catheter will be provided. The course will also include hands-on practice on phantoms and human models.

The pre-congress course is designed for physicians, nurses and healthcare professionals interested in the field of vascular access placement and management in children.

This pre-congress course is organised by the ESA Scientific Subcommittee on Paediatric Anaesthesia.

Hour session: 09:00 – 18:00

Friday 2 June 2017

Geneva

Pediatric Vascular Access Courses

SonoSite FUJIFILM

ULTRASOUND TRAINING COURSES

PAEDIATRIC ULTRASOUND GUIDED VENOUS ACCESS

A One-Day Practical Course for physicians and nurses

Pending 6 RCR Category 1 CME Credits

COURSE DIRECTOR

Dr Thierry Pirotte
Consultant Anaesthetist
Université Catholique de Louvain
Belgium

PROGRAMME

Monday 24th July 2017

08.30	Registration and coffee
09.00	**Lecture:** Ultrasound physics and knobology applied to (very) small vessels
09.20	**Lecture:** US-guided vascular punctures in children
09.50	**Practical:** Machine knobology and needling towards small (2mm) in vitro vessels.
10.30	Morning break
10.50	**Lecture:** US anatomy and puncture of the internal jugular vein in children
11.10	**Lecture:** US anatomy and puncture of the femoral vessels in children
11.20	**Lecture:** US anatomy and puncture of the «subclavian» vein in children
11.45	**Practical:** Scanning the neck and the supra & infraclavicular area on live paediatric models
13.00	Lunch
13.45	**Lecture:** Ultrasound-guided PICC Line insertion in children
14.05	**Lecture:** Arterial and venous peripheral access in children
14.15	**Practical:** Scanning the arm and forearm area in live paediatric models + review different approaches and needling techniques
15.45	Afternoon break
16.00	Summary & Question time
16.30	Close

Monday 27 July 2017

Luton - UK